# PAPER - II (शल्यतंत्र) (PA)

## अस्थि - Skeletal Injuries

Clinical features
Diagnosis
complications
Management

- scapula
- clavicle
- Humerus
- Radius
- ulna
- femur
- patella
- tiba
- Pelvic Region bones.

Rib Fracture

## संधिभ्रंश - (Dislocation)

- Clinical features
- Diagnosis
- complications
- Management

## Disease of Bone

- Osteomyelitis — (1)
- cyst — (2)
- Tumors — (3)
- Tuberculosis — (4)
- congenital Anomalies. — (5).

- Perthe's diseases
- Osteogenesis Imperfecta
- club foot
- spina Bifida.
- Osteosarcoma

- Osteo Malacia
- Osteoporosis
- Osteo Arthritis

- Cranio-cerebral Injuries (CCI)

- Diseases of spine — Tuberculosis — Pott's disease
  - Ankylosing spondylitis — Ankylosing
  - Slipped Disc Prolapse

- Disease of Breast — स्तन विद्रधि
  - Breast Abscess.
  - स्तन अर्बुद — (Breast tumors)
  - CA of Breast
  - Phyllotid tumor
  - Duct papilloma

- Chest injury (23)
  - Pleural Effusion — Lung Abscess.
  - Pleurisy — Lung cancer
  - Tumors

- Diseases of Esophagus — Congenital Anomalies
  - congenital oesophageal Atresia
  - Oesophagitis — Hiatus Hernia
  - Varices — Sliding Hernia
  - Rolling Hernia
  - CA of oesophagus ulcer and tumors
  - Oesophageal Perforation
  - Cork screw oesophagus

- Varices
- गुल्म रोग
- शूल व्याधि
- उदर रोग — जलोदर — Ascites
  - छिद्र — Perforation, Peritonitis
  - आंत्र अवरोध — Intestinal obstruction.

- Diseases of Stomach and Duodenum
  - Congenital Hypertrophied.
  - Helicobacter Pylori Infection.
  - Pyloric Stenosis
  - Helicobacter Pylori Infection
  - Peptic ulcer (gastric ulcer, duodenal ulcer)
  - Tumors (CA of stomach)
  - Scapot deformity
  - Hourglass contracture
- Diseases of small Intestine
  - Tuberculosis
  - Intussusception
  - Volvulus
  - obstruction
  - Meckel's diverticulum.
  - Perforation
  - Paralytic ileus.
  - IBS.
- Disease of Large Intestine
  - Tuberculosis
  - Obstruction
  - Volvulus.
  - Perforation
  - Appendicectomy
  - Tumors
  - Appendicitis
  - Crohn's diseases
  - ulcerative colitis.
- Diseases of Rectum and Anal-canal
  - भगंदर
  - गुदा-पुट
  - Haemorrhoids
  - (Fistula in Ano)
  - परिगुदीय
  - गुदा पिडका
  - Fissure in Ano
  - (Anorectal Abscess)

- गुदभ्रंश - Rectal Prolapse
- गुदसंकोच - Anal Stricture
  - Incontinence
  - Rectal Polyp.
  - Tumors
- Abdominal Injuries and Management -

# FRACTURE

- A complete break down of Bone
- Fractures also occurs :
  - Cartilage — ①
  - Epiphysis — ②
  - epiphyseal plate — ③

Factors -

- Causes — ①
- Types — ②
- Clinical features — ③
- Signs — ④
- Investigations — ⑤
- Treatment — ⑥.
- complications — ⑦.
- Healing of fractures — ⑧.

① Causes. – harga bones. —— ①
– suddenly occurs —— ②
– Chronic force —— ③
– repetitive force —— ④
– Prolonged standing. —— ⑤
– Natural Resistance —— ⑥

• Types. – Simple —— ①
– Fracture line —— ②
– Plane fracture —— ③
– Fracture causes —— ④
– Atypical fractures —— ⑤

① Simple fracture – Soft tissue Break —— ①
– soft tissue damaged. —— ②
– also called closed fractures. —— ③

② Fracture line -

- Incomplete fracture — ①
- complete fracture — ②.

① Incomplete fracture -

- Not Involve full shaft — ①
- Intact Portion — ②

② complete fracture -

- Displaced fracture — ①
- Bone thickness dis continued — ②.

). Plane fracture -

- Transverse fracture — Perpendicular to axis — ①
- spiral fracture — surface is spiral — ②
- oblique fracture — surface forms an Angel. — ③.
- compression fracture — compaction of Bone — ④.

## (4) Fracture cause –

- Traumatic fracture — (1) — Due to some load.
- Pathological fracture — (2) tumor/Infection
- Stress fracture — (3). Seen in Athletes.

Incomplete fracture

## (5) Atypical fractures –

- Green stick fractures — (1)
- Impacted fractures — (2)
- Crack fractures. — (3)
- Torus fracture — (4).

• Clinical features –

- Pain — (1)
- Swelling — (2)
- Deformity — (3)
- Loss of function — (4).

- Signs -

- Tenderness — (1)
- Swelling — (2)
- Abnormal Mobility — (3)
- Loss of Movements — (4)
- Crepitus — (5)
- Shortening — (6).

- Investigations -

- X-Ray — (1)
- CT-Scan — (2)
- MRI Scan — (3)

- Anteroposterior view — X-Ray — (1)
- Lateral view — (2)

Treatment -

- Conservative treatment -
  - Strapping
  - Plaster slabs
  - P.O.P.
  - NSAID's

— Through closed Reduction

① — Resuscitation — ①

② — Reduction — closed Reduction — ②

— continous traction — ③

— Open reduction — ④

Open Reduction — Displaced Intra-articular fractures

Relative

③ Retention — splintage — ①

P.O.P splints — ②

Braces — ③

④ Rehabilitation — Elevation — ①

Active excercise — ②

— Open Reduction — Exposure — ①

— Reduction — ②

— Temp. stabilization — ③

— Definitive stabilization — ④.

## Acute complications

- Shock — (1)
- Acute Respiratory Distress — (2)
- Neuro-Vascular Injuries — (3)
- Compartmental Syndrome — (4)
- Crush Syndrome — (5)
- Thrombosis — (6).

## Peculiar complications

- Infection — (1)
- chronic Osteomyelitis — (2)
- gas gangrene — (3)
- Tetanus — (4)
- Hypovolaemic shock — (5).

- Healing of fracture –

– Stage of Haematoma formation — (1)
– Stage of granulation — (2)
– Stage of callus — (3)
– Stage of Remodelling — (4)
– Stage of modelling — (5)

Abraham

# Colles fracture (वि: प्रकोष्ठास्थि अधोप्रान्त भग्न)

- A colles fracture is a type of Broken wrist (fracture)
- Also called a distal fracture with dorsal Angulation.
- Serious Injury

- Factors -
  - Cause — ①
  - Clinical features — ②
  - classification — ③
  - Investigation — ④
  - Treatment — ⑤

- cause - common Mode of Injury is slip and fall with dorsiflexion pattern.
  - 60% females.

- **Fracture pattern** -

  - Usually sharp — (1)
  - palmer Aspect — (2)
  - dorsal surface — (3)
  - Radius surface — (4)

- **Clinical features** -

  - H/o fall on outstretched Hand — (1)
  - Pain — (2)
  - swelling — (3)
  - deformity — (4)
  - Dinner fork deformity — (5)
  - Styloid Process. test — (6)

- **classification** -

  - Extra-articular — (1)
  - Intra-articular — (2) (Radiocarpal)
  - Extra-articular — (3) (Radioulnar joint)
  - Intra-articular — (4) (Radiocarpal and Inferior Radioulnar)

## Investigations -

- X-Ray — Anterior Posterior — (1)
  - Lateral View : — (2)

## Treatment -

- Fracture Reduction — (1)
- Fragments — (2)
- displaced fragments — (3)

# SMITH's Fracture

Palmar displacement
Hence it is called as (Reverse colle's fracture)

## Factors –

- Mechanism — ①
- clinical features — ②
- Investigations — ③
- Treatment — ④

## Mechanism of Injury

- Fall on the Back of Hand — ①
- Direct blow — ②
- Fall on forearm in supination — ③.

- Clinical features -

— Pain — (1)
— Swelling — (2)
— deformity — (3)
— loss of wrist function — (4)
— Garden spade deformity — (5)

- Investigation -
  - Radiography. — (1)
  - X-Ray. — (2)
  - Anterior Posterior View — (3)

- Treatment -
  — Closed Reduction — (1)
  — Immobalization — (2)
  — Fixation — (3)
  — open Reduction — (4)
  — plate fixation — (5)

# Clavicle fracture (अक्षकास्थि भग्न)

A break in the Bone connecting the breastbone and shoulder.

**Factors** —

- Mechanism — ①
- Fracture site — ②
- clinical features — ③
- Treatment — ④

① **Mechanism** —

- **Direct** — Point of shoulder (91%) — ①
  - Direct trauma over clavicle (08%) — ②

- **Indirect** — Fall on outstretched Hands (1%) — ①.

- Sites of fracture -

- Middle and outer 3rd — (1)
- Medial end } (5%) — (2)
- Lateral end } (15%) — (3)

• Clinical features -

- Pain — (1)
- Swelling — (2)
- Deformity — (3)
- Tenderness — (4)
- Inability — (5)
- Pseudo-paralysis — (6)

• Treatment -

- Cuff and collar sling — (1)
- Strapping — (2)
- Billington yoke Method — (3)
- Internal fixation — (4)

# Femur fracture (उर्वास्थि भग्न)

- subtrochanteric fracture — (1)
- Fracture Neck of femur — (2)
- Femoral condyle fracture — (3)
- Supracondylar fracture — (4)
- Fracture shaft of femur — (5)

- combination of osteoporosis or osteomalacia (12%) common in elderly women secondary to senile osteoporosis.

**Mechanism**
- Slip and fall in bathroom — (1)
- Lateral Rotation of extremity — (2)
- Muscles force and torsion — (3)
- Major trauma — (4)

- Classification

- Broad classification — (1)
- Structural classification — (2)
- Anatomical Location. — (3)
- Pauwel's — (4)
- Perlington — (5)

- Clinical features —

- Pain in Bones. — (1)
- Movements Restriction — (2)
- Tenderness — (3)
- Rotational deformity — (4)
- Impacted fracture — (5)
- Hip Movements Restricted — (6)

## Investigations -

- X-Ray — (1)
- Lateral view of Hip joint — (2)
- CT-Scan — (3)

## Treatment -

- Surgery - Orthopaedic emergency.

## Garden classification of Hip fractures.

- Garden stage I — (1)
- Garden stage II — (2)
- Garden stage III — (3)
- Garden stage IV — (4)

- Garden I - conservative Hip Spica is applied — ①

- Garden II - Complete fracture — ①
  - Dynamic Hip Screw — ②

- Garden III — conservative treatment
  - surgery is best choice.

Garden Classification of HIP fractures

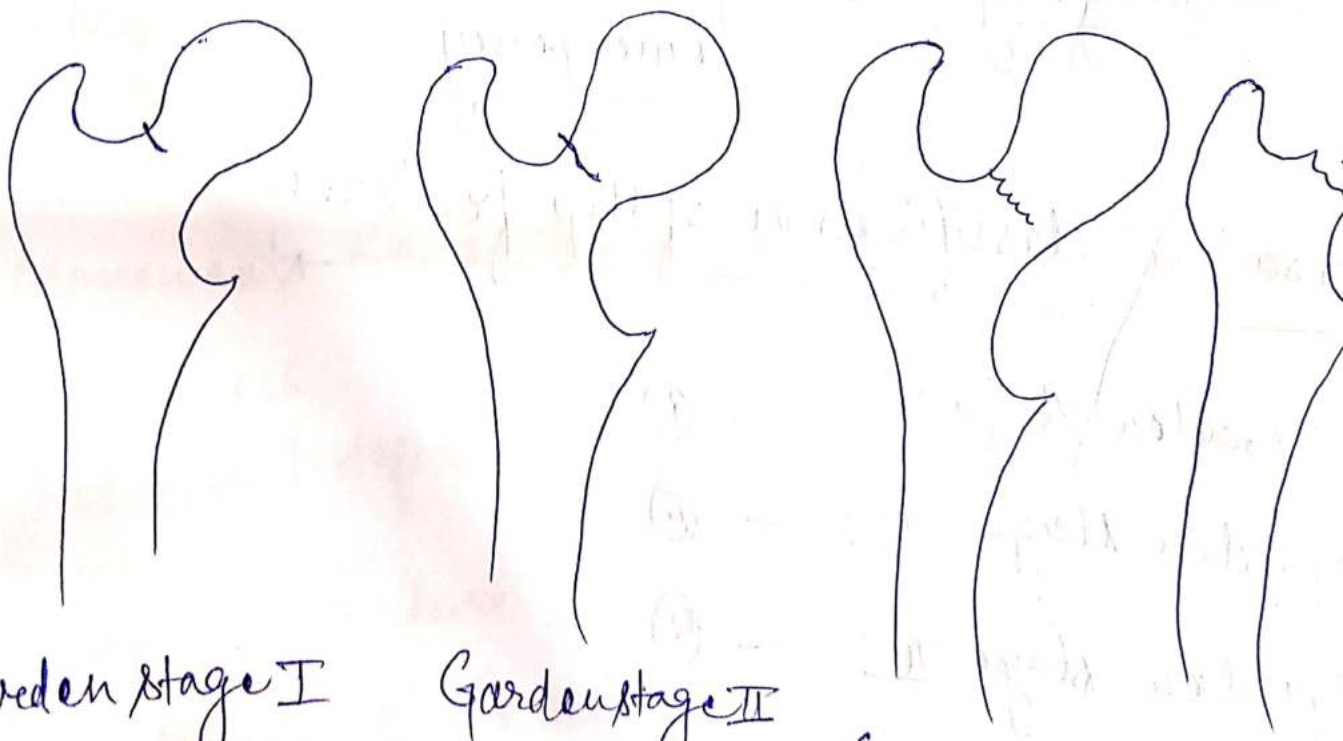

Garden stage I — undisplaced, Incomplete

Garden stage II — undisplaced complete

Garden stage III — Complete fracture Incomplete displaced

Garden stage [illegible] — Complete fracture complete displ[illegible]

# Patella fracture (जानुसंधि भग्न)

- A patella fracture is a break down of knee cap
- Traumatic Injury mainly.

## Factors -

- Mechanism — ①
- Incidence — ②
- classification — ③
- clinical features — ④
- Treatment — ⑤

## Mechanism -

- Direct trauma — ①
- Indirect trauma — ②
- Direct trauma - due to direct fall over the patella
- Indirect trauma - Quadriceps contraction.
  - Sudden forcefull contraction

- **Incidence** -

  - Age - 20-50 yrs — (1)
  - M:F = 2:1 — (2)

- **Classification** -
  - Undisplaced — (1)
  - Displaced. — (2)

- **Undisplaced** - Transverse fracture — (1)
  - Stellate fracture — (2)
  - Vertical fracture — (3)

- **Displaced** - Transverse fracture — (1)
  - Oblique fracture — (2)
  - Vertical Fracture — (3)
  - Comminuted fracture — (4)
  - Polar — (5)
  - Osteochondral fracture — (6).

## Clinical features -

- Trauma — (1)
- Pain — (2)
- Swelling — (3)
- Movements Restricted — (4)
- palpable gap — (5)
- Tenderness — (6)
- sign — (7)
- positive patellar tap — (8)

## Investigations -

- X-Ray — (1)
- CT Scan — (2)

## Treatment -

- undisplaced
  - compression Bandage — (1)
  - Ice Application — (2)
  - Aspiration — (3)
  - Cylindrical cast in extension — (4)
  - Cast Brace — (5)

② Displaced –

- open Reduction — ①
- Internal fixation — ②
- Patellectomy — ③
- Anterior tension — ④
- cannulated screw fixation — ⑤

# RIB Fracture (पर्शुकास्थि भग्न)

- Rib cage cracks. fracture called as Ribfracture

**Factors** -

- clinical features — (1)
- Treatment — (2)

**Clinical features** -

- Pain — (1)
- Tenderness — (2)
- Breathing difficulty — (3)
- Disturbed sleep — (4)
- travelling difficulty — (5)

**Treatment** -

- Intercoastals Muscles immobilization — (1)
- strapping — (2)
- Ultrasound — (3)
- Local Infiltration — (4)
- Deep breathing exercise — (5)

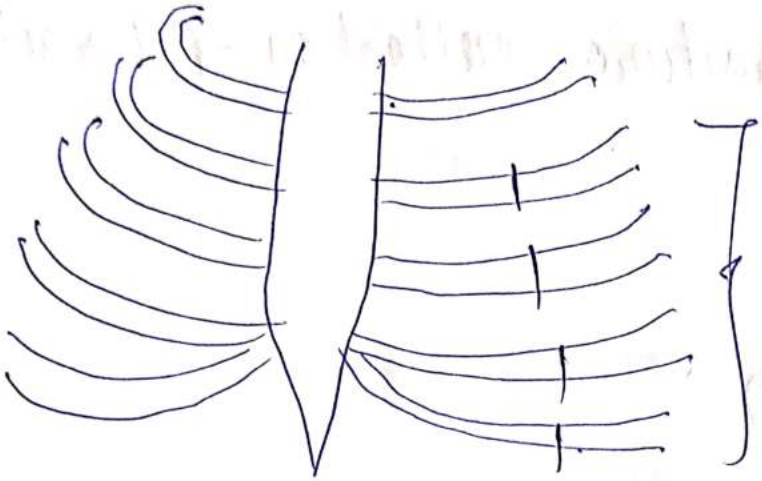

Broken Ribs

(Rib fracture)

# भग्न - सन्धिमुक्त (Fracture and Dislocation)

- भग्न - Discontinuity of Bone — (1)

- सन्धिमुक्त - Incapibility of extension and flexion movement

निदान - पतन — (1)
- पीडन — (2)
- प्रहार — (3)
- आक्षेपण — (4)
- त्याल भूमिदान — (5)
- बलवद विग्रह — (6)
- अभिघात — (7)

- भग्न प्रकार -

- Acc० सुश्रुत - अस्थि भग्न — (1)
  - सन्धिमुक्त — (2)

- Acc० वाग्भट - अस्थि भग्न — (1)
  - सन्धि भग्न — (2).

- A/c to मध्यकोष =
  - सम्रण — ① (Open)
  - अम्रण — ② (Closed)

- Clinical features
  - खंजबाहुल्य — ①
  - स्पन्दन — ②
  - विवर्तन — ③
  - स्पर्श सहिष्णुता — ④
  - अवपीडन शब्द — ⑤
  - स्तब्धता — ⑥
  - विविध वेदना प्रादुर्भाव — ⑦
  - सर्व अवस्था — ⑧

- संधिगुक्त Clinical features
  - Extension
  - flexion
  - Circumduction

  } Inability — ①

  - severpain — ②
  - Hyperesthesia — ③

## काण्ड भग्न प्रकार / Classification –

- कर्कट —— (1) Fracture with Haematoma K
- अस्त्रक वि —— (2) oblique fracture A
- चूर्णित —— (3) comminuted fracture C
- पिचित —— (4) compression fracture P
- अस्थि च्छल्लित —— (5) Sub-Periostal Haematoma A
- काण्ड भग्न —— (6) Traverse fracture K
- मज्जानुगत —— (7) Impacted fracture M
- अतिपातित —— (8) complete fracture A
- वक्र —— (9) Green stick fracture V
- छिन्न —— (10) Incomplete fracture C
- पाटित —— (11) cracked fracture
- स्फुटित —— (12) Fissured fracture

• सन्धिमुक्त प्रकार –

- अपिष्ट —— (1) Dislocation
- विश्लिष्ट —— (2) Subluxation
- विवर्तित —— (3) Lateral displacement
- अवक्षिप्त —— (4) downward displacement
- अतिक्षिप्त —— (5) Overriding
- तिर्यक्क्षिप्त —— (6) oblique displacement.

- अपिष्ट – Swelling on both sides. —— (1)
- विश्लिष्ट – slight swelling —— (2)
- विवर्तित – Lateral displacement —— (3)
- अवक्षिप्त – joint separation —— (4)
- अतिक्षिप्त – pain and overriding —— (5)
- तिर्यक्क्षिप्त – obliquely displaced. —— (6)

साध्य / असाध्य -

- कृच्छ्रसाध्य - कृश — (1) — चूर्णित
  - वृद्ध — (2) — चिन्न
  - बाल — (3)
  - क्षतक्षीण — (4) — अतिपातित
  - कुष्ठ — (5) — मज्जानुगात
  - श्वास — (6)

  difficult to cure

- असाध्य - skull fracture
  - waist fracture
  - dislocations
  - subluxation
  - Hip bones crushing

  disgraded

- Effects - तरुण अस्थि — Bends — (1)
  - नलकास्थि — Breaks. — (2)
  - कपालास्थि — Cracks. — (3)
  - रुचकास्थि — Fragmented — (4)

• Principles –

– भग्न स्थापन — ①
– कुशबन्धन — ②
– कर्मवर्तन: — ③

– भग्न स्थापन – Reduction — ①
– कुशबन्धन – Retention — ②
– कर्मवर्तन – Rehabilitation — ③

• भग्न स्थापन –
- अवकर्षण (Traction)
- पीडन (Pressure).
- Splints – मधुक Bark
- Bandanging – उपचार
  - अश्वत्थ
  - पलाश
  - काकुभ
  - Bamboo.
  - सर्ज
  - Banyan

- पथ्य/अपथ्य -

(पिण्ड)

- पथ्य - शाली Rice — (1)
  - मांस रस — (2)
  - घृत — (3)
  - दुग्ध — (4)
  - Pea soup — (5)

- अपथ्य - लवण आहार — (1)
  - कटु आहार — (2)
  - मैथुनात — (3)
  - व्यायाम — (4)
  - रूक्ष अन्नमेव — (5)

चिकित्सा - Local Applications
- मजिष्ठा
- मधुका
- शाली पिण्ड
- Banyan
- रक्त चन्दन
- शत धौत घृत
- श्यामत्रोध कषाय
- पञ्चमूल द्रव्यों
- चक्र तैल

- Dislocations –

– नखसंधि भग्न — (1)
– अंगुलि भग्न — (2)
– पादतल भग्न — (3)
– teeth Injury — (4)
– नासा भग्न — (5)
– शिरस कपाल — (6)
– Sprains — (7).

(1) नखसंधि भग्न – (Nail bed Injury)
Subungual Haematoma

(2) अंगुलि भग्न – (Fingers fracture)

(3) पादतल भग्न – (Foot fractures)

(4) teeth Injury – (loose and Bleeding teeth)

(5) नासा भग्न – (Nasal fracture)

(6) शिरस कपाल भग्न (Skull fracture)

(7) Sprains.

## Fracture bed (फ्रैक्चर शय्या)

- Incase of leg fracture and thigh fracture फ्रैक्चर शय्या is Beneficial.

- 05 pegs should be fixed by wise surgeon — (1)
- 02 pegs on each side by wise surgeon — (2)
- 01 pegs at the foot-end should be fixed — (3)

factors -

- Mal union of fractures. — (1)
- Dislocation of Hip joint — (2)
- Dislocation of elbow joint — (3)
- Dislocation of knee joint — (4)
- Dislocation of Ankle joint — (5)
- Dislocation of wrist joint — (6)

## Procedure -

- Sesamum seeds left overnight — (1)
- dried during the day — (2)
- then treated with cow's milk (1 week) — (3)
- Added (मधूक कषाय) in 2nd week — (4)
- Again treated with cow's milk — (5)
- drying and Powdered — (6)
- मधूक, मञ्जिष्ठा, सारिवा, कुष्ठ, सर्जरस जटामांसि, देवदारु, शतपुष्प (Powdered and Added with Seasamum चूर्ण)
- Posted with पुरुष by a Physician
- oil should be cooked and Mixed with क्षीर or the Quantity of चूर्णs.

## Indications

- Fractures — (1)
- Dislocations — (2)
- Hemiplegia — (3)
- Facial paralysis — (4)
- Lock Jaw — (5)
- Convulsions — (6)
- Palate Dryness — (7)
- Neck stiffness — (8)
- Deafness — (9)
- Earache — (10)

## Benefits

- Neck, chest
  shoulder gets दृढ़ — (1)
- Face becomes fair — (2)
- Cures दाँतों की पीड़ा — (3)
- श्वास कास कारक — (4)

diagram

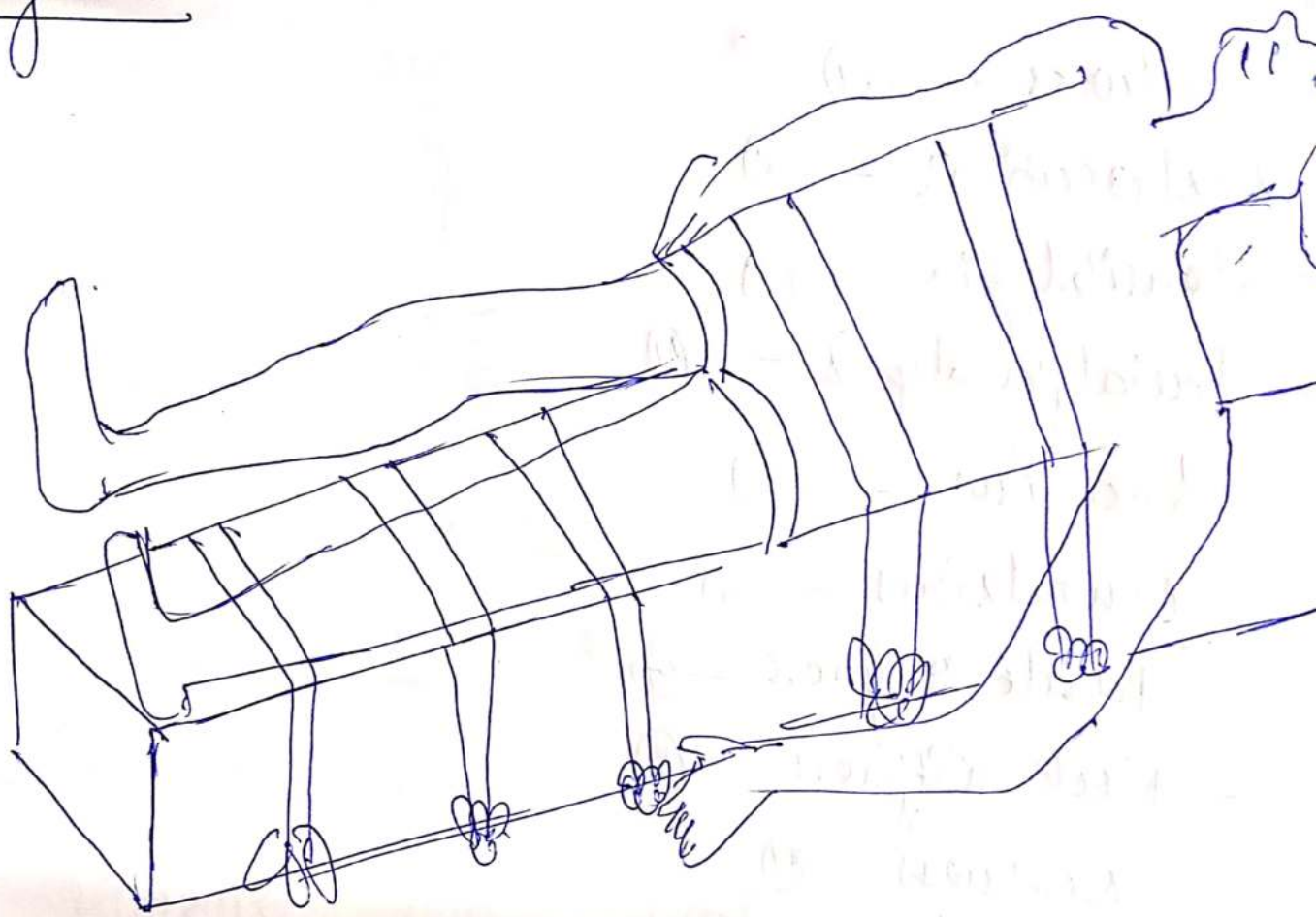

: fracture bed diagram :

# • संधि मोक्ष ( अंस सन्धि मोक्ष)

- Shoulder Has an 'Achilles point' at the inferior part of capsule providing joints.

- Shoulder dislocation
  - Anterior Dislocation — ①
  - Posterior dislocation — ②

- Ref - शल्यतंत्र / surgery

- Anterior dislocation -
- Posterior dislocation —

Factors -

- Mechanism — ①
- clinical features — ②
- test — ③
- X-Rays findings — ④
- Techniques. — ⑤.

- Mechanism — Direct force — (1)
  — Indirect force — (2)
  — Direct force — posterior Aspect
  — Indirect force — Abduction + External Rotation + extension Injury.

(2) clinical features —
  — severe pain — (1)
  — External Rotation — (2)
  — Restricted Adduction — (3)
  — shoulder contour lost — (4).

(3) clinical test — Posterior Area flat — (1)
  — Coracoid process — (2) unidentified
  — Axillary Nerve Injured — (3).

- Investigations -
  - X-Ray — (1)
  - glenoid cavity defect — (2)
  - A-Inferior Defect — (3)
  - P-Lateral Defect — (4).

- Techniques -
  - Closed Reduction — (1)
  - Open Reduction — (2)
  - Kocher's Method — (3)
  - Stimson's Method. — (4)

Posterior dislocation -
- Direct force — (1)
- Indirect force — (2).

- Direct force - Anterior Aspect
- Indirect force - Adduction + Internal Rotation + flexion Injury.

- Clinical features – Sewerap sin — (1)
  - Rotation Restricted — (2)
  - Abduction is Restricted — (3)
  - contour lost — (4)

- Clinical test – Anterior portion is flat — (1)
  - Carocoid Process prominent — (2)

- Investigations –
  - X-Rays — (1)
  - Antero-~~lateral~~ (lateral) defect — (3)
  - Anterior glenoid Possa — (4)

- Techniques – Reduction under general Anaesthesia — (1)
  - Distal traction — (2).

(हनुसंधि मोक्ष)

# Dislocation of temporo Mandibular joint

- Dislocation of Temporal Bone
- Attached with Mandible bone (Jaw Bone)

of surgery

Factors —

causes — (1)

Types — (2)

clinical features — (3)

Treatment — (4)

(1) Causes — Chin Trauma — (1)
— Forceful opening — (2)
— Dental operations — (3)
— Ligament weakness — (4).

(2) Types — Partial — (1)
— unilateral — (2)
— Acute — (3)
— Anterior — (4).

- Clinical features –
  - open lock —— ①
  - Difficulty in speech —— ②
  - Drooling of saliva —— ③
  - Lip Incompetency —— ④
  - palpation —— ⑤

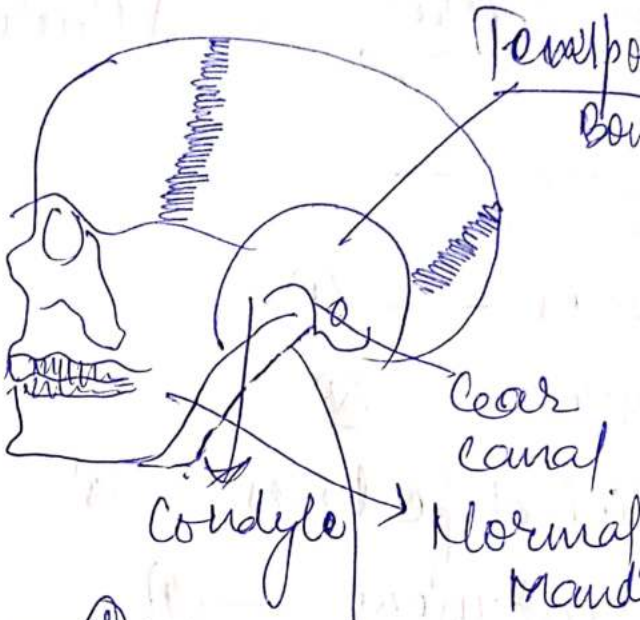


- Treatment –
  - Manual Reduction —— ①
  - Surgery (open Reduction) —— ②.

- संधिमोक्ष – मुसले नोत्क्षिपेत् —— ①
  - कक्षामांस सन्धौ —— ②
  - विसंहते —— ③
  - स्वस्तिकेन —— ④.
  - विलक्षणः —— ⑤.

# Diseases of Bone

## Osteogenesis Imperfecta –

- Also called Brittle Bone diseases
- A group of inherited disorders characterized by fragile Bone that Break easily.

## Factors –

- Aetiology — ①
- Types — ②
- Symptoms — ③
- Diagnosis — ④
- Treatment — ⑤

Healthy Bone

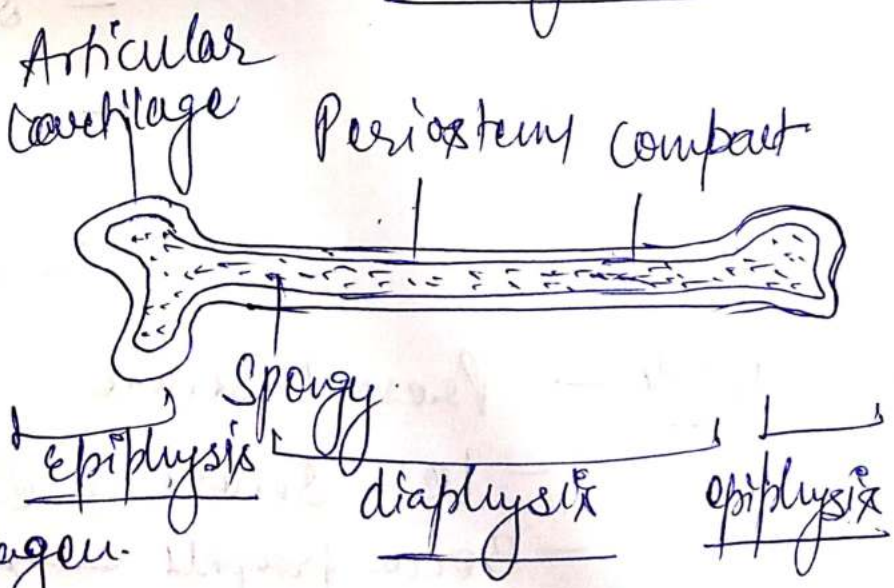


① Aetiology –

- Lack of – type I collagen.
- Mutation of – COL1A1 } genes.
  COL1A2

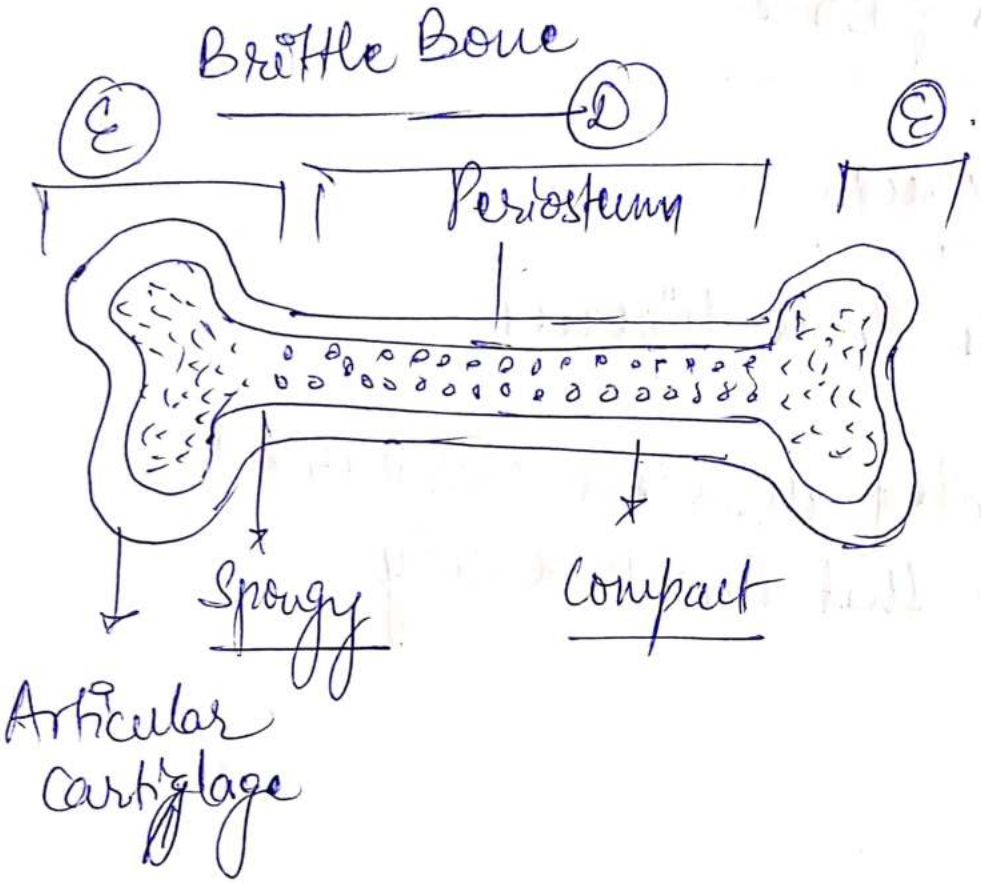


- Types - Congenital - Multiple fracture — (1)
  - Dwarfism — (2)
  - Severe deformities — (3)
  - usually die reaching Adult life — (4)

Tarda - Present severe — (1)
- Less severe — (2)
- Bone fragils — (3)

Symptoms. -

- Bone bendness — (1)
- Short height — (2)
- Scoliosis — (3)
- loose joints — (4)
- Bowed legs — (5)

Diagnosis -

- DNA testing
- X-Ray — Osteoporosis — (1)
  - shaft of Bones — (2)
  - —

Treatment -

- Maintain lifestyle — (1)
- IV Pamidronate — (2)
- wheel chairs. — (3)
- Kebab treatment — (4).

## Clubfoot –

- Also called – talipes equinovarus.

- A Birth defect in which the foot is twisted out of shape or position

Factors –

- causes — ①
- clinical features — ②
- deformities — ③
- Treatment — ④

① causes – early Amniocentesis — ①
- underdevelopment of Bones — ②
- underdevelopment of Muscles — ③
- constriction of foot under uterus — ④
- Genetics — ⑤

- Clinical features —

— Dorsiflexed foot — (1)
— Convex foot — (2)
— calf Muscles — (3)
— Foot size smaller — (4)
— Adduction — (5)

- Deformities —

— Equinous deformity — (1)
— Calcaneus — (2)
— Varus deformity — (3)
— Valgus — (4)
— Cavus deformity — (5)
— Planus — (6)
— Splay — (7)

- Treatment —

- Ponseti Method —— ①
- French Method —— ②
- Postero Medial Release surgery —— ③

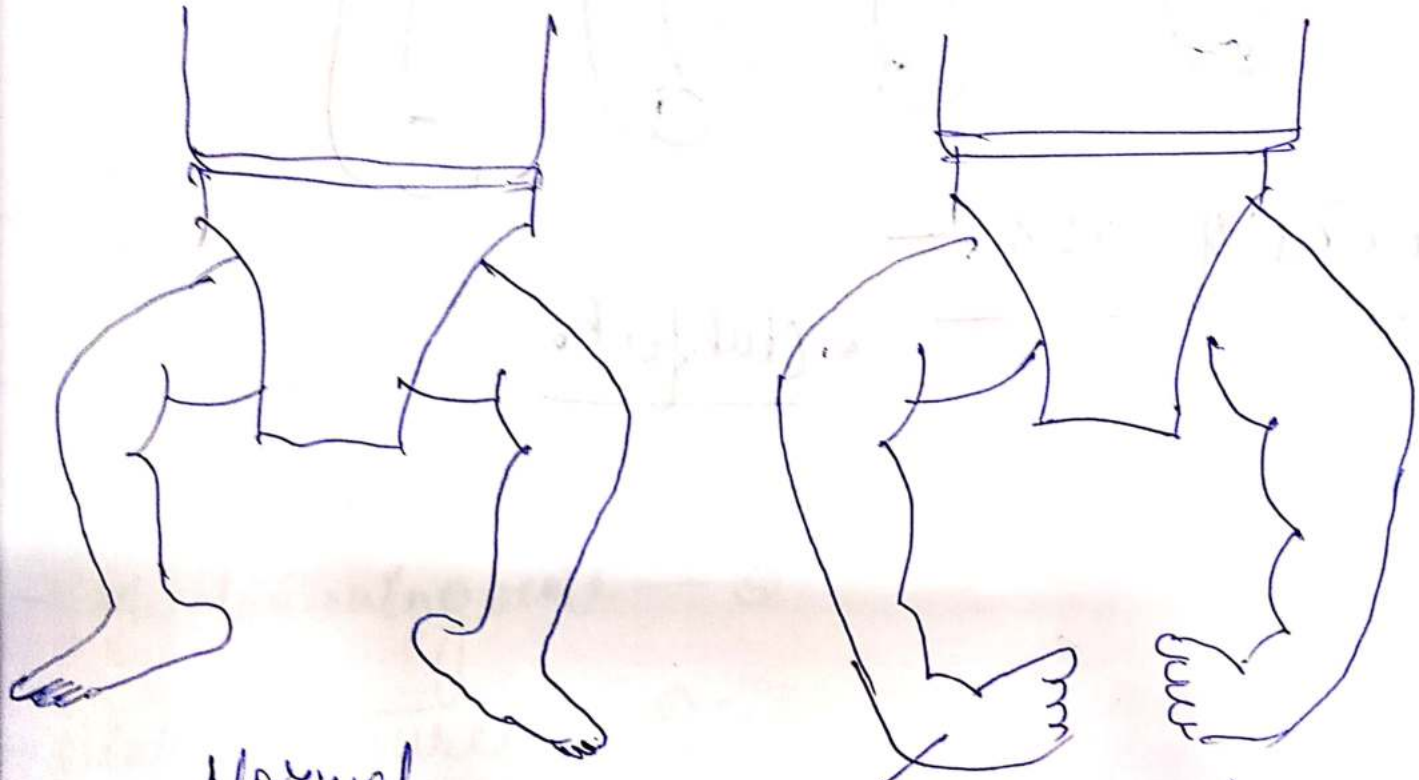

Normal

Club foot

Foot pointed down and in

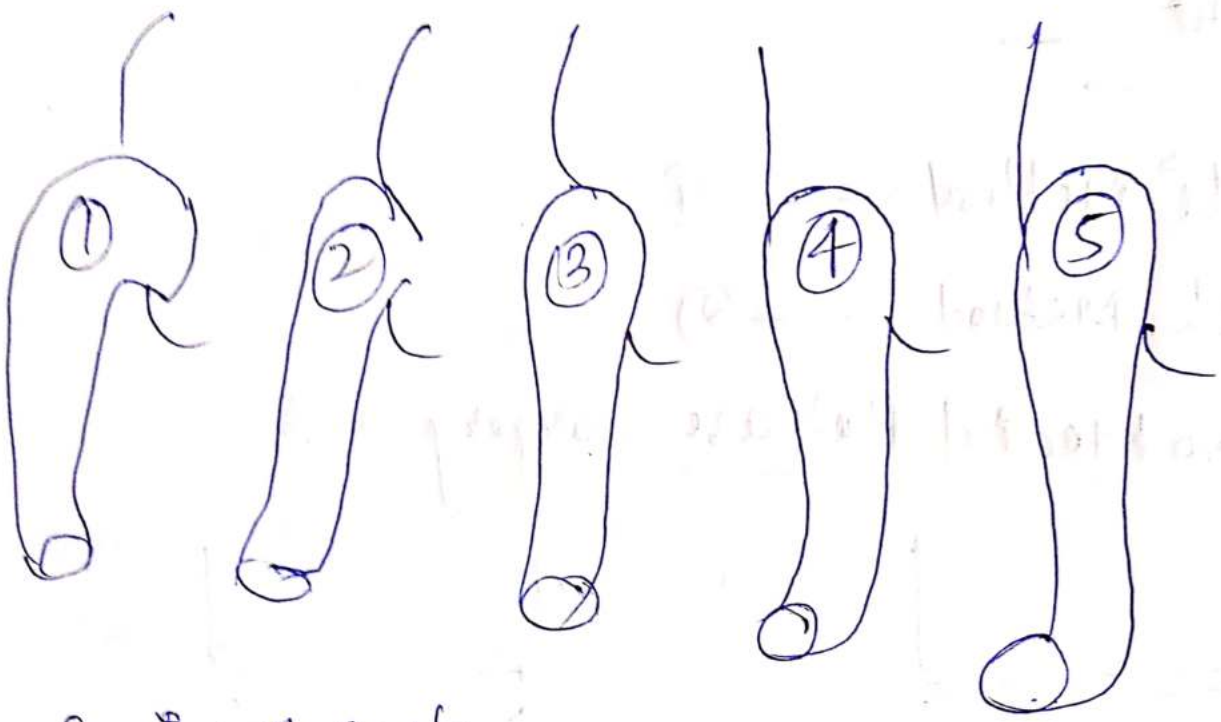


- Series of casts —
- Clubfoot.

# Spina Bifida

- Incomplete closing of Backbone and Membranes around Spinal cord.

- Lumbosacral — (1)

- Factors —

- Causes — (1)
- Types — (2)
- Meningocele — (3)
- Myelomeningocele — (4)
- clinical features — (5)
- Investigations — (6)
- Treatment — (7)

) Causes. — Failure of unfolding Nerve — (1)
— Not enough folate — (2)
— Alcohol — (3)
— Anti seizure Medications — (4)

(1) Meningocele — (1)

— Spinal cord fail to develop properly (small gap).

— Neural tubes defects — (1)

— 1 out of every 1000 Births — (2)

— Most common in Lumbo-sacral Region — (3)

— May occur in skull. — (4)

— Mostly well covered by skin — (5)

— Asymptomatic in Nature — (6)

— Constipation — (7)

— Bladder dysfunction — (8).

(2) Meningo myelocele — (2)

(3) Syringo Myelocele — (3)

(4) Myelocele — (4)

(5) Spina Bifida occulta — (5)

2) Spina Bifida Occulta –
– doesnot fully form.

3) Meningomyelocele –
– spinal canal and Backbone doesnot close.

– Spina Bifida occulta
– Meningocele
– Meningocele Myelocele
– Syringo Myelocele
– Myelocele

4) Syringo Myelocele –
fulfilled defect.

Myelocele – Neural tissue of spinal cord exposed.

Clinical features

– Leg weakness. —— ①
– paralysis —— ②
– orthopaedic Abnormalities. —— ③
– Bladder and bowel control. —— ④
– Skin irritations —— ⑤
– Abnormal eye Movements —— ⑥.

- **Investigations** –

  – USG —— (1)
  – Amniocentesis —— (2)

- **Treatment** –

  – Surgery —— (1)
  – Development of limb function —— (2)

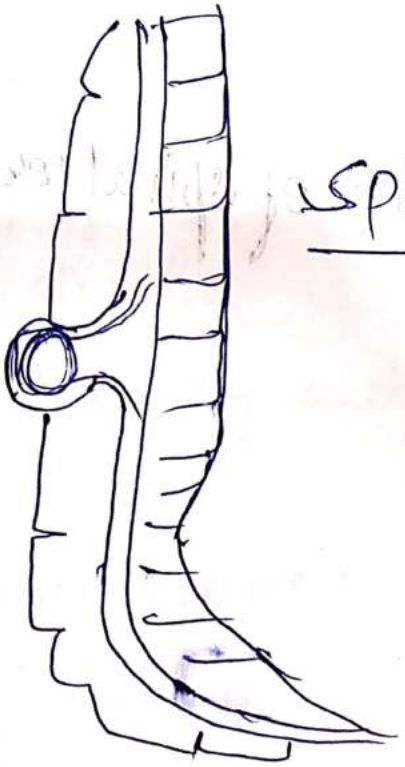

**Spina Bifida** –

# Osteomyelitis

- Inflammation of Bone caused by Infective organisms.

Factors -

- Long bones of leg — (1)
- arms — (2)
- Hip — (3)
- knee — (4)
- shoulder — (5)
- wrist joint — (6)
- Pelvis (Hip) — (7)

Classification →
- Acute Pyogenic Osteomyelitis — (1)
- chronic Osteomyelitis — (2)
- sub Acute Osteomyelitis — (3).

# Acute Pyogenic Osteomyelitis

- Acute Inflammatory process of Bone caused by pyogenic organisms.

• Factors

- Aetiology — (1)
- Site — (2)
- Pathology — (3)
- Symptoms — (4)
- Investigations — (5)
- complications — (6)
- Treatment — (7)

(1) Aetiology
- Causative organisms — (1)
- Haematogenous. — (2)
- Direct — (3)

- Site - Metaphysis

Pathology - suppuration — (1)
- Necrosis — (2)
- New Bone formation — (3)
- superficial tissue — (4)




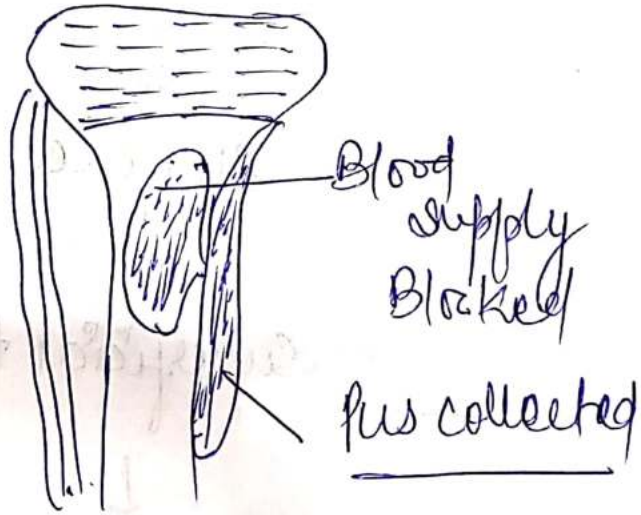




— Stage of suppuration — (1)

↓

— Stage of Necrosis — (2)

↓

— Chronic osteomyelitis starts — (3)

↓

— Involucrum — (4)

↓

— Cloacae — (5)

↓

— Superficial tissue attached — (6)

↓

— Osteomyelitic sinus occurs — (7) (8)

Symptoms -

- Pain ——— (1)
- Movement affected — (2)
- Swelling ——— (3)
- Pus ——— (4)
- Tiredness. ——— (5)
- Headache ——— (6)
- Tenderness - ——— (7)

Investigations.

- Routine Blood Examination. ——— (1)
- X-Rays — (2)
- USG — (3)
- MRI — (4).

Complications - Septicaemia — (1)

- Pyaemia — (2)
- Bacteraemia — (3)
- Toxaemia — (4).

## Treatment -

- General — Antibiotics
  - Analgesics.
  - Antipyretics.
  - Rest

- Local — Splintage — ①
  - Drainage — ②

- Splintage — immobilize the joints and Bones above and Below the fracture site.

03 types — long leg post. splint — ①
- Stirrup splint — ②
- Ankle splint — ③

# Chronic Pyogenic Osteomyelitis

- Two types.
  - Acute Osteomyelitis — ①
  - Brodies abscess — ②

Prolonged Infection of the Bone upto 6 weeks.
mainly Adults

- Clinical features
  - Minimum Pain — ①
  - Swelling — ②
  - granulation — ③
  - Fever — ④
  - Hardness of Bone — ⑤

- Investigations
  - Increased ESR — ①
  - Increased CRP — ②
  - X-Ray — Dense — ①
    - irregular — ②
    - space around — ③
    - Involucrum — ④.

- Treatment -

— conservative — Antibiotics — (1)
— diet — (2)
— Anti-Anaemic treatment — (3)
— Blood transfusion — (4)

— Brodies Abscess - — walled off by fibrous granulation tissues

— Clinical features

— Bony pain — (1)
— tenderness — (2)
— swelling — (3)
— Effusion — (4)

- Investigation

— X-Ray — (1)
— CT Scan — (2)

— Treatment — Surgical evacuation — (1)
— curettage — (2)

- आयुर्वेद — अपमार्ग क्षार तैल — (1)
— क्षार वर्ती — (2).

## • Osteo sarcoma –

– Osteogenic sarcoma

– Type of Bone cancer that Begins in the cells that form Bones.

– Occurs in long Bones.

– Factors –

– Site — (1)
– Causes — (2)
– classification — (3)
– clinical features — (4)
– Investigations — (5)
– Treatment — (6).

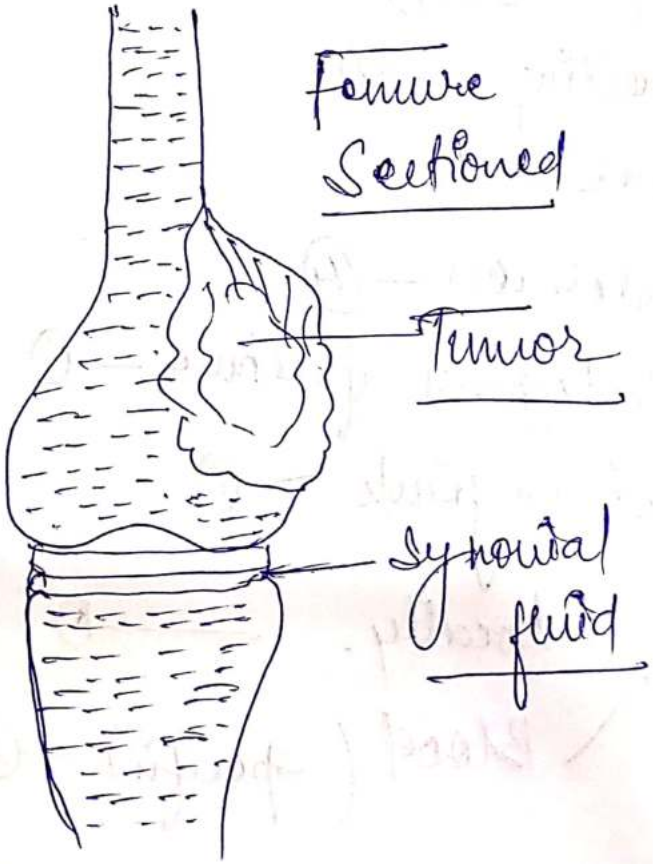


) Site – Metaphysis — (1)
– osteo blast cells — (2)
– Knee (70%) — (3)
– Femur (52%) — (4)

Tibia — (26%)
Humerus — (9%)

- Causes – Radiotherapy — (1)
  - Familial — (2)
  - Bone dysplasias — (3)
  - Trauma — (4)

- Clinical features –
  - Pain — (1)
  - swelling — (2)
  - Fever — (3)
  - Tenderness — (4)
  - pathological fracture — (5)
  - pain in joints — (6)

Spread
- Locally. — (1)
- Blood (specific). — (2).

Treatme
- Amputat
- Chemoth

- Investigations – X-Ray — (1)
  - CT-scan — (2)
  - MRI — (3)
  - Bone Biopsy — (4)

# Bone tuberculosis (अस्थि क्षय)

- Secondary diseases — ①
- Local Manifestation — ②
- Bronchial lymph gland — ③ (Primary site)
- spreads through Blood — ④

## Factors —

- predisposing factors — ①
- Pathology — ②
- Features — ③
- Investigations — ④
- Treatment — ⑤

## Pre-disposing factors —

- Debility — ①
- Malnutrition — ②
- Anaemia — ③
- Local ~~[illegible]~~ — ④
  trauma

## – Pathology –

- Metaphysis — (1)
  ↓
- Synovial Memb. thick — (2)
  ↓
- Articular Cartilage Involves. — (3)
  ↓
- Calcium fad up. — (4)
  ↓
- Ligaments degeneration — (5)
  ↓
- Tubercular caseation spreads. — (6)
  ↓
- Tubercular sinus formed — (7)
  ↓
- Tuberculosis (TB) occurs — (8)

## Features -

- Pain — (1)
- Swelling — (2)
- Disability — (3)
- Deformity — (4).

## Investigations -

- Montoux test
- X-Ray
- Biopsy

## Treatment
- General
- Local

**General** -
- Rest — (1)
- Nutrition food — (2)

**Local** -
- Rifampicin — (1)
- Ethambutol — (2)
- Isoniazid — (3)
- Pyrazinamide — (4).

# Osteomalacia

- directly co-relates with the softening of the bones.
- Problem occurs because of vitaD.
- This condition also co-relates with the rickets.

## Factors

- clinical features — (1)
- Investigations — (2)
- Treatment. — (3)
- preventive measures. — (4)

## clinical features -

- Age — (1)
- Bone pain — (2)
- Hip pain — (3)
- pathological fracture — (4)
- General malaise — (5)
- Fissure fractures — (6)
- tenderness (7).

- Investigation -

- Low calcium — (1)
- Low phosphate — (2)
- Radiology — (3)
- Bone Biopsy — (4).

- Treatment -

- 800 - 4000 IU oral dose of vit-$D_2$ - $D_3$. } Rickets
- 5000 IU vit D.

- 1 gm of calcium lactate ($CaCO_3$) orally } Osteomalacia
- calciferol 1 mg/day

- Preventive Measures.

- Education — (1)
- Periodic dosing — (2)
- vit D fortification — (3).

# Osteoporosis

- A condition in which Bones become weak and Brittle.

Factors –

- Causes — (1)
- Pathology — (2)
- Investigations — (3)
- Treatment — (4)

Causes –

- Local Inflammation — (1)
- Prolonged Immobilized — (2)
- Steroids usage — (3)

Pathology – oldage / Post – Menopausal

↓

oestrogen level down / decrease

↓

Bone Remodeling capacity down

↓

decrease in osteoblast cells.

↓

Osteoclast cells occurs.

↓

Osteoporosis occurs.

eg - Colle's fracture — ①
- Crush fracture — ②
- Femur Neck fracture — ③

- Investigation -
  - X-Ray — ①
  - CT scan — ②
  - MRI — ③

- Treatment -
  - Diet (Vita D rich) — ①
  - Calcium Rich diet — ②
  - Exercise — ③
  - Biophosphonates — ④.

# • Osteo-arthritis (OA) •

- degenerative joint disease — ①
- Breakdown of joint cartilages — ②

## ctors -

Classification — ①
Common factors — ②
clinical features — ③
Investigations — ④
- Treatment — ⑤

## ) Osteo Arthritis classification -

- Primary Osteoarthritis — ①
- secondary Osteoarthritis — ②

## Common factors -

- Knee — ①
- Hip — ②
- spine — ③

## Clinical features -

- Pain — ①
- Stiffness — ②
- Joint locking — ③
- Joint Instability — ④.

## Investigations -

- Radiography — ①
- CT-scan — ②
- X-Ray — ③

## Treatment - NSAIDs — ①

- Analgesics — ②
- Injections — ③

## Non-Pharmacological Measures -

- Reduction — ①
- Patient education — ②
- Exercise — ③
- Orthotics — ④.

## आयुर्वेद Mana

- जानु बस्ति
- रसना सप्तक
- योग मुद्गर
- अग्नि कर्म

## Surgery -

- Osteotomy
- Arthroplasty
- Arthrodesis
- Excision

# PERTHES Disease

- Legg-calve-Perthes disease
- Disorder of the hip in young children.
- Ages - 4 and 10

Factors -

- Def — ①
- Clinical features — ②
- Investigations — ③
- Treatment — ④.

Def - Child Hip disorder initiated By a disruption of Blood flow.

Clinical features -

- Hip Pain — ①
- Knee pain — ②
- Hip pain — ③
- Atrophy — ④
- Inflammation — ⑤
- Trendlenburg test Positive — ⑥.

- Investigation

- X-Ray — (1)
- Later defragmented — (2)
- Femoral Head — (3)

- Treatment -

- Traction — (1)
- Orthotics — (2)
- Surgery — (3)
- Braces — (4).
- Physiotherapy — (5).

# EWING'S SARCOMA / TUMOR

A cancer that most often occurs in and around the Bones.

- occurs more in childrens and young Adults.

Factors -

- Site — ①
- causes — ②
- clinical features — ③
- Investigations — ④
- Treatment — ⑤

Site - Tibia — ①
- Humerus — ②
- Femur — ③
- Fibula — ④
- clavicle — ⑤

Cause - Trauma
- Translocation of chromosomes - 11 and 22

- Clinical features -
  - Bone Pain — (1)
  - Swelling — (2)
  - Red skin — (3)
  - Dilated Veins — (4)
  - Fever — (5)
  - Anaemia — (6)
  - Leucocytosis — (7).

- Investigations -
  - X-Ray — (1)
  - Onion Layer Appearence — (2)

- Treatment -
  - Surgical Resection — (1)
  - Local Radiotherapy — (2)
  - Systemic Chemotherapy — (3).

# Diseases of spine

## Pott's diseases / TB spine (कुबड़ा रोग)

Spinal tuberculosis (TB).

commonest extrapulmonary Manifestation of TB.

- spreads through Hematogenous Route

Factors –

- Varieties — ①
- Pathology — ②
- clinical features — ③
- Investigation — ④
- Treatment — ⑤

Varieties →
- central — ① ✓
- Metaphyseal — ② ✓

① central -

- Mainly affects body of Vertebrae — ①
- Gradually Bone Become soft — ②
- Leads to deformity of spine — ③

② Metaphyseal -

- Involves in epiphysis — ①
- Blood supply - Lower half of one Vertebrae — ②
  - Upper half of Vertebrae — ③

• Pathology -

TB settles
↓
causes tubercular (endarteritis)
↓
Follicle developed
↓
Nodule size Increases
↓
spinal Angular deformity (Gibbus)

## Clinical features -

- Pain at site — (1)
- stiffness — (2)
- swelling — (3)
- Attitude — (4)
- Tenderness — (5)
- weakness — (6)
- coin test — (7)

## Investigations -

- X-Ray — (1)
- MRI — (2)
- CT scan — (3)

## Treatment -

- Anti tubercular drugs — (1)
- SPICA — (2)
- Drainage — (3)

# Ankylosing spondylitis

- It's a chronic progressive Inflammatory disea
- It's Associated with HLA - B27 gene
  Human Lymphocyte Antigen
  (Bechterew's diseases)

- factors -
  - Types — ①
  - clinical features — ②
  - Treatment — ③
  - Pathology — ④

① Types - True — ①
- False — ②

True
- Fibrous Ankylosis — ①
- Bony Ankylosis — ②

- Fibrous Anky - Articular cartilage Damage -
  - Fibrosis occurs — ②
  - joints limits — ③

Bony - Major damage articular cartilage — ①
- No Movement is Possible at joint — ②

False Anky - extra articular lesion — ①
- joints in limit — ②
- Not directly Involved — ③

Pathology - Initial Inflammation of joints — ①
- Synovitis — ②
- Arthritis — ③
- cartilage — ④
- destruction — ⑤
- Sacro iliac joints — ⑥
- manubrium sterni — ⑦. Costosternal joint

Clinical features - Malaise — ①
- fatigue — ②
- Stiffness — ③
- Flechel's test — ④
- Tenderness — ⑤

SLR Test — ⑥.

- Treatment -
  - General Measures — (1)
  - Conservative therapy — (2)
  - Surgery — (3)

- General Measures
  - Patient — (1)
  - Family education —
  - Avoid smoking — (3)
  - Regular exercise — (4)
  - Physiotherapy —

(2) Conservative therapy -
  - Rest — (1)
  - Radiotherapy — (2)
  - Fusion of the spine
  - costosternal joint
  - Plantar fasciitis

(3) Surgery -
  - Spinal osteotomy — (1)
  - Hip Ankylosis — (2) (replacement)
  - Knee Replacement — (3)

# Disc Prolapse

## Intervertebral / slipped Disc

Herniated Disc — ①

spinal disc Herniation — ②

A condition which refers to a problem with a rubbery disc b/w the spinal Bones.

Factor —

- causes — ①
- Common site — ②
- Types — ③
- features — ④
- Investigations — ⑤
- Treatment — ⑥

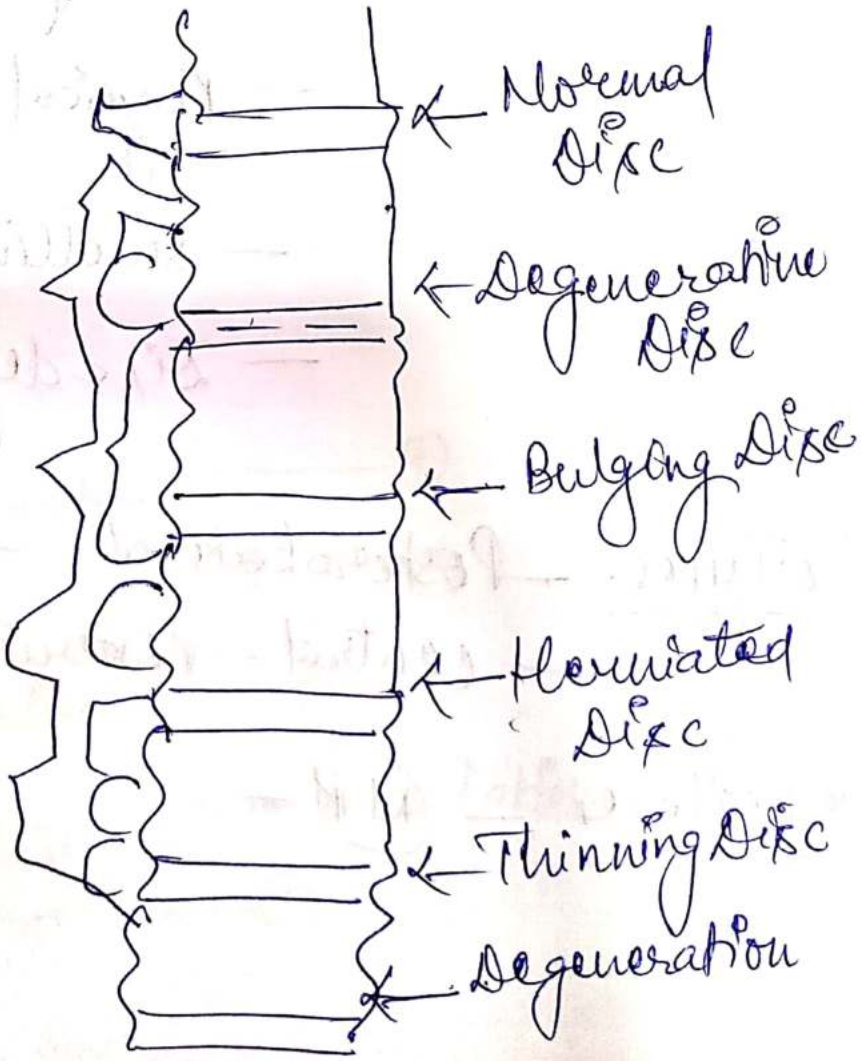

— Causes —

— External — Trauma (80%) — (1)
— workers — (2)
— porters — (3)
— trekkers — (4)

— Internal — Over weight — (1)
— thin Body — (2)
— Hyper function of Back bone — (3)
— Physical illness — (4)
— Smelling — (5)
— Disc degeneration — (6)

• Types. — Postero Lateral — (1)
— central — Posterior — (2)

• features — (NP) —

features -

- low Backache — (1)
- Pain Radiates — (2)
- Tenderness — (3)
- lumbar — (4)
- flexions Restricted — (5)
- +ve SLR test — (6)

Investigation -

- X Ray — (1)
- Radiulo graphy — (2)
- CT - Scan — (3)
- MRI — (4).

Treatment - Spinal Jacket — (1)

- Hot fomentation — (2)
- Analgesics. — (3)
- Electrical Nerve stimulation — (4)
- Surgery — (5)

## आयुर्वेद चिकित्सा –

- कटिबस्ति — (1)
- मात्र बस्ति — (2)
- त्रयोदशांग गुग्गुलु — (3)
- निर्गुण्डी तैल — (4)
- रसना सप्तक कषाय — (5)

# CCI Cranio-Cerebral Injuries

- Cerebral contusion — ①
- Sub-Arachnoid Haemorrhage — ②
- Extra-Dural Haemorrhage — ③
- Head Injury — ④.

## Cerebral contusion —

- Scattered areas of Bleeding on the surface of the brain.

## Factors —

- Clinical features — ①
- Treatment — ②
- Glas Gow Coma scale — ③
- Investigation — ④
- Management — ⑤

① Clinical features -

- Headache — ①
- Confusion — ②
- Sleepiness — ③
- Dizziness — ④
- Unconsciousness — ⑤
- Tinnitus — ⑥
- Nausea — ⑦
- Vomiting — ⑧

- Treatment -

- Hypotension — ①
- Hyponatremia — ②
- Hypercapnia — ③

- Glasgow coma scale
  - Eyes open — ①
  - Best Verbal response
  - Best Motor Response

- Glass Gow Coma scale

- eyes open — spontaneous – 04 — (1)
  To speech — 03 — (2)
  To Pain — 02 — (3)
  None — 01 — (4)

- Best Verbal Response
  - oriented — 05 — (1)
  - confused — 04 — (2)
  - Inappropriate — 03 — (3)
  - Incomprehensible sound — 02 — (4)

- Best Motor Response
  - verbal command — 06. — (1)
  - localize Pain — 05 — (2)
  - withdrawl to Pain — 04 — (3)
  - flexion — 03 — (4)
  - extension — 02 — (5)

- Mild Head Injury — 13-15
- Moderate Head Injury — 9-12
- Severe head Injury — 3-8.

- Less than 07 in coma

- Investigation
  - X-Ray — (1)
  - CT Scan — (2)
  - Electrolyte study — (3)
  - Blood group — (4)

- Management -
  - Airway — (1)
  - General Assessment — (2)
  - Care of unconscious — (3)
  - Drugs. — (4)
  - Surgical Management — (5)

- Drugs
  - IV fluids
  - Analgesic
  - Diuretics
  - Antibiotics
  - Corticosteroids.

Surgical Management
- Craniotomy — (1)
- Cranial flap — (2)
- Clot is evacuated

# Haemorrhage

Haemorrhage
- extradural — ① (epidural)
- sub-dural — ②
- subArachnoid — ③

**Extra-Dural** — collection of Blood in extradural space B/w duramater and skull.

Factors -
- Site — ①
- Causes — ②
- Features — ③
- Investigations — ④.

① Site - Temporo - Parital Region.

② Causes. - Injury to dural Venous — ①
- Middle Meningeal Artery — ②.

- **Features** -
  - H/o Blow or fall — (1)
  - Lucid Interval — (2)
  - Confusion — (3)
  - Irritability — (4)
  - Hutchinsonian Pupil — (5)
  - Raised Intracranial pressure — (6)

- **Investigation** -
  - X-Ray skull — (1)
  - CT scan — (2)

- **Treatment** -
  - Immediate Craniotomy — (1)
  - Evacuation of Haematoma — (2).

## Sub-dural Haemorrhage -

- collection of Blood b/w brain and dura (subdural space).

Factors -
- Site — (5)
- Cause — (1)
- features — (2)
- Investigations — (3)
- Treatment — (4).

Cause - Common in old age — (1)
- Minor trauma — (2)

Site - cortex of brain — (1)

Features - unconsciousness — (1)
- convulsions — (2)
- Bilateral Headache — (3)
- Intracranial Pressure ↑. — (4).

- Investigations -

— CT scan

- Treatment -

— Antibiotics — (1)
— Anticonvulsants — (2)
— general anesthesia — (3)
— craniotomy — (4).

- Sub-Arachnoid Haemorrhage

— collection of Blood in subArachnoid space

- Factors -

— causes — (1)
— Features — (2)
— Investigations — (3)
— Treatment — (4).

Causes - Intracranial Aneurysm — ①
- Hypertension — ②
- Brain tumors — ③
- Anticoagulants — ④

Features - Headache — ①
- Vomiting — ②
- Intracranial pressure — ③
- Neck stiffness — ④
- photophobia — ⑤
- Ptosis — ⑥
- dilated Pupil — ⑦

Investigations - Lumbar puncture shows blood stain CSF
CT Scan

Treatment - Craniotomy
- Ligation of common carotid artery.

## • Head Injury :
## (Cranio cerebral trauma)

— Brain dysfunction
— caused by outside force

• Factors —
- Injury to scalp. — ①
- Injury to skull — ②
- Brain Injury — ③

- Injury to scalp :-

— scalp Lacerations — ①
— exsanguinating Haemorrhage — ②
— scalp's Rich vascular supply — ③

• Injury to skull —

— common in children — ①
— single or multiple — ②
— Anterior or Middle — ③
— dural Venous sinuses — ④.

Types -

- Linear fracture — (1)
- Simple fracture — (2)
- Depressed — (3)
- Skull Base — (4)

Linear fracture -

- Compression of sphere — (1)
- Skull distorsion — (2)
- Linear fracture — (3)
- Extradural Haemorrhage arises — (4)

Simple fracture -

- Blunt trauma — (1)
- Radiate to skull — (2)
- No fracture — (3)
- Acceleration of Primary Brain Injury — (4).

Depressed -

- Depressed — (1)
- sharp trauma — (2)
- Inner part affected — (3).

- Fragments depressed
- cortical damage.

- Skull Base — Subdivided into Anterior — (1)
  - Middle — (2)
  - Posterior cranial fossa — (3)

- Anterior cranial fossa fracture
  - CSF Rhinorrhoea — (1)
  - sub-conjunctival Haemorrhage — (2)
  - Anosmia — (3)
  - Blindness — (4)
  - Dilated Pupil — (5)

- Middle cranial fossa fracture —
  - Fracture of Maxillary — (1)
  - Abducent, facial Nerve palsy — (2).

- Posterior cranial fossa fracture
  - Boggy swelling in Nape — (1)
  - Battle sign — (2).

# Traumatic Brain Injury

Two types of Injury –

- primary Injury —— (1)
- secondary Injury —— (2).

- Direct Impact Injury —— (1)
- Acceleration Injury —— (2)
- shock wave Injury —— (3)

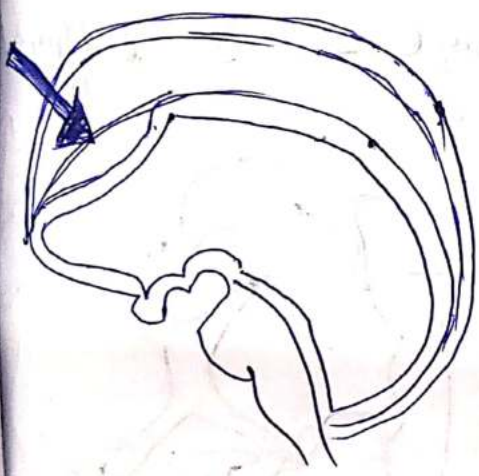

Direct Impact Injury

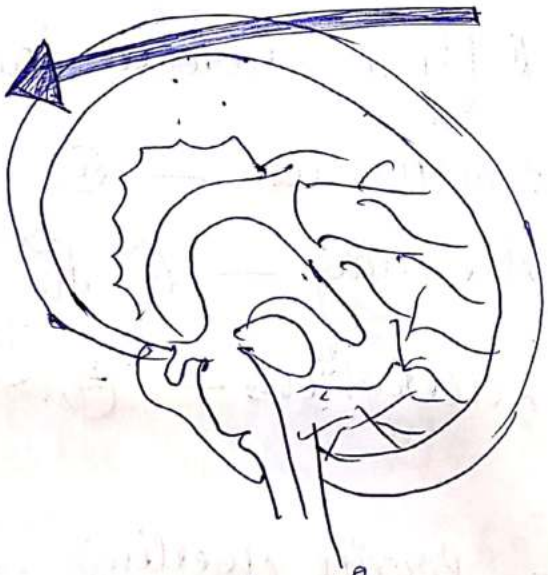

• Acceleration deceleration Injury

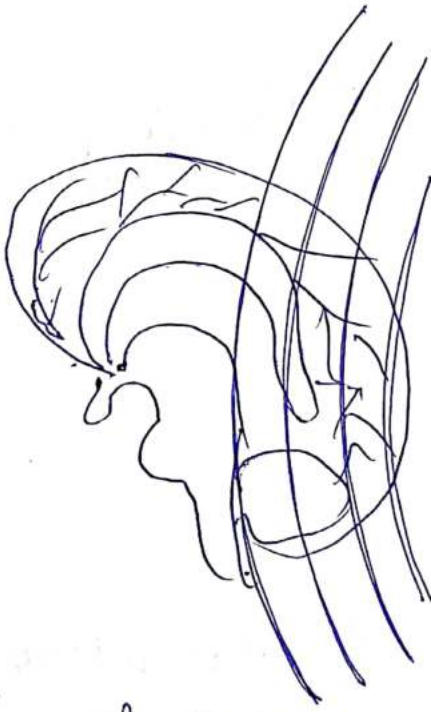

• Shock wave Injury

- Causes :-
  - Brain distortion — (1)
  - Brain Mobility — (2)
  - Deceleration Injuries — (3)
  - Acceleration Injuries — (4)
  - cerebral damage — (5)
  - Coup Injury — (6)
  - coning — (7).

(1) Primary
- Diffuse Neuronal damage — (1)
- contusions — (2)
- shearing — (3)
- Lacerations — (4).

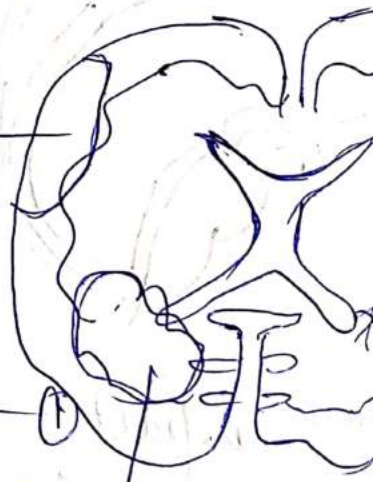

Sub dural (H)

Intra Cerebral (H)

(2) Secondary
- Brain swelling — (1)
- Haemorrhage — (2)
- Infections — (3)

- Otherfeatures
  - CSF Leaks — (1) Panda sign
  - Blood collection — (2) Haematoma scalp
  - Battle's sign — (3)

# Diseases of Breast

## Breast Abscess.

Breast abscess are painful, pus filled lumps under the skin of Breast

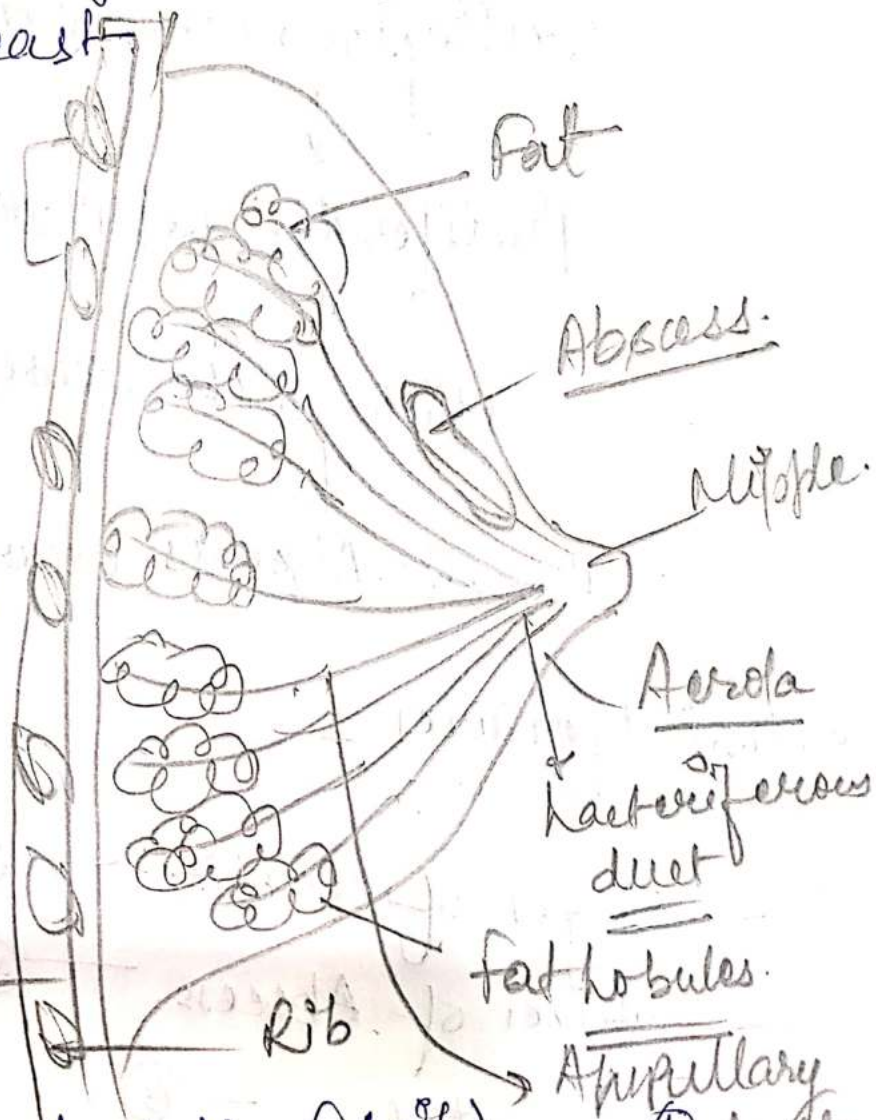


**Factors** —

- Key points — ①
- Pathology — ②
- Clinical features — ③
- Treatment — ④
- complications — ⑤.

**Key points** —

- Encountered during lactation (60%) — ①
- Precipitating factors —
  - Crack in Nipple — ①
  - Retracted Nipple — ②
  - Improper cleaning — ③
  - Injection ~~cleaning~~ — ④
  - Haematoma — ⑤.

- Pathology -

- sucking in cracked Nipple — (1)

↓

Staphylococcus Aureus Bac — (2)

↓

Proliferates and Block it — (3)

↓

Milk Clott occurs — (4)

↓

Breast Abscess occurs — (5)

- clinical features -

- Stages of cellulits — (1)
- Stages of Abscess — (2)
- untreated — (3)

- Treatment - Advice
  - Not to feed — (1)
  - Nipple Moisturizer — (2)
  - Good support to Breast

Treatment -

Small - wide excision of lump.
subcutaneous Mastectomy

Giant - simple Mastectomy
Quadrantectomy

Diagram -

# Phylloid tumor

- Phylloid tumor directly co-relates with the Benign tumor of Breast.
- Grows Rapidly and attains great size.
- Benign — 85% — (1)
- Borderline — 15% — (2)

- Factors
- clinical features — (1)
- Treatment — (2)

## clinical features.

- More common — 30-50yrs — (1)
- usually unilateral — Bosselated surface — (2)
- Swelling — (3)
- Soft — (4)
- Non-tender — (5)
- Skin stretched — (6)
- dilated Veins. — (7)
- Tumor is warmer — (8).

Stage of cellulitis

- Antibiotics — (1)
- Anti-Inflammatory drugs — (2)
- Anti-Pyretic — (3)
- Non-Lactational Breast Abscess — (4)

Position - Supine — (1)

Anaesthesia - GA — (2)

Preparation - Painting, Drapping — (3)

Incision - In Radial direction about 5-6 cm in Made over swelling.

Procedure - Pyogenic abscess.

- Another Incision is Made on dependent position and corrugated rubber drain

- Cavity May be Packed with roller gauze.
- Stop oozing Haemorrhage from its wall and Prevent formation of Haematoma.

- Closure - Do not close incision
  - If Infection is very severe.

- Complications -
  - Antibioma formation — (1)
  - Skin Necrosis — (2)
  - Sinus — (3)
  - Recurrent Infection — (4)

# Breast tumors (Fibro Adenoma)

Growth composed of Both fibrous and gladular tissue

Hyper plasia of single Lobule of Breast.

Factors -

- Types — (1)
- clinical features — (2)
- Investigations — (3)
- Treatment — (4)
- Benign Neoplasm of Breast — (5)

Type — Grossly — Soft — (1)
- Giant — (2)
- Hard — (3)

- microscopically -
  - Intra canalicular — (1)
  - Pericanalicular — (2)

- Intracanalicular —
  - Large — (1)
  - Soft — (2)
  - Less fibrosis — (3)
  - Cellular type — (4)
  - Stroma — (5)
  - Proliferated — (6)

- Pericanalicular —
  - Mainly fibrous — (1)
  - Stroma — (2)
  - Breast Mouse — (3)

- Clinical features —
  - Painless lump in Breast — (1)
  - Breast is smooth — (2)
  - Axillary lymph Nodes — (3)

- Investigation —
  - Mammography — (1)
  - FNAC — (2)
  - USG — (3)

- Treatment —
  - Gallbird Ho Incision
  - Webster's
  - Enucleation

# Duct Papilloma

Benign single wart growth in lactiferous duct is called duct papilloma.

Factors –

Clinical features — (1)
Investigation — (2)
Treatment — (3)

Clinical features –

- Middle Aged (30-50yrs) women's — (1)
- Bloody discharged from Nipple — (2)
- Small type of swelling — (3)

Investigation – Ductogram.

Treatment – Microdochectomy

- आयुर्वेद चिकित्सा – शिवमुष्टिका —— (1)
  - Ashoka अरिष्ट —— (2)
  - Tab Ferrigared gold. —
  - Tab diazen. —— (4)

Papilloma

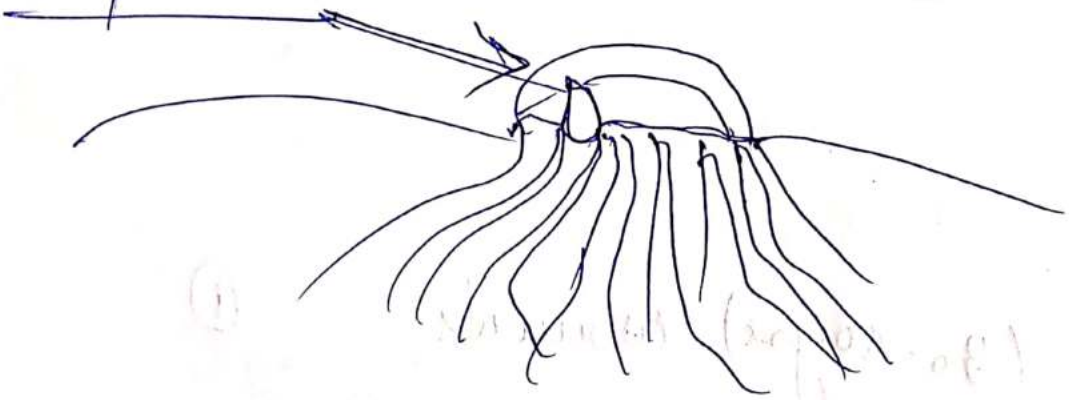

# CA of Breast (स्तन अर्बुद)

Carcinoma of Breast

Calcium deposition within Breast tissue

Breast calcifications.

Ref — शल्य तंत्र / surgery

Factors -

- Aetiology — (1)
- Site — (2)
- Classification — (3)
- clinical features — (4)
- examination — (5)
- Spreadness — (6)
- TNM classification — (7) (CA)
- Treatment — (8).

Aetiology - ABCDEFGH.

- Age - Below Age 20 yrs
  - 40-60 yrs of Age.

② Breast cancer and syndrome —

— Li-fraumeni syndrome (LFS) — ①
— Cowden's diseases — ②
— Ataxia telangiectasia — ③

③ Child Bearing and Infertility

— Nulliparous women.

④ Diet — Increased Risk —

— Post Menopausal — ①
— Alcohol More than drinks /day — ②
— Excessive saturated fat — ③
— Vitamin C — ④

⑤ Endocrine.

— Early Menarche — ①
— Early Menopause — ②
— Oestrogen Level Imbalance — ③
— Hormonal Replacement therapy (HRT) —

## Female sex -

- Females — 99% — (1)
- Males — (1%) — (2)
- gynaecomastia → CA — (B)

## General Points -

- CA in Breast — (1)
- IHA 30% — (2)
- 2-4% Bilateral — (3)
- 2-5% Hereditary — (4)
- 75% Breast — (5) (lump)
- 10% lump in Breast — (6).

## Site -

- 60% — (1) CA cervix — (1)
- 12% — (2) inner Quadrant (upper)
- 10% — (3) inner Quadrant (Lower).
- 06% — (4) lower Quadrant (Lower)
- 12% — (5) Sub areolar Region.

- Classification -

- Unilateral — 90% — (1)
- Bilateral — 2-5% — (2)

- Ductal CA — 90% — (3)
- Lobular CA — 10% — (4)

- unilateral — (5)
- Multifocal — (6)
- Multicentric — (7)

- Infiltrating CA — (8)
- Non-Infiltrating CA — (9).

- CA types. -

- Infiltrating — (1)
- scirrhous CA — (2)
- Medullary CA — (3)
- Inflammatory CA — (4)
- colloid CA. — (5)
- Paget's diseases. — (6).

rgetts diseases of Nipple.

Clinical features -

- Lump in Breast — (1)
- Bleeding per Nipple — (2)
- Retraction of Nipple — (3)
- Ulceration — (4)
- Enlarged axillary lymph Nodes — (5)

Clinical examination -

- Inspection — (1)
- Palpation — (2)
- Axillary lymph Node examination — (3)
- examination Metasis — (4).

Spread - Local — (1)
- Lymphatics. — (2)
- Blood — (3)
- TNM Stage — (4).

- Investigations -

— Mammography — BI-RADS

— BI-RADS — 0 — (1)
— BI-RADS — 1 — (2)
— BI-RADS — 2 — (3)
— BI-RADS — 3 — (4)
— BI-RADS — 4 — (5)
— BI-RADS — 5 — (6)
— BI-RADS — 6 — (7)

— USG — (2)
— FNAC 95% — (3)
— Biopsy — (4)
— Investigation — (5)

- Treatment -

— Surgery — (1)
— Radiotherapy — (2)
— Hormonal therapy — (3)
— chemotherapy — (4)

• Surgeries -

- Local Excision — (1)
- Quadrantectomy — (2)
- Total Mastectomy — (3)
- Patey Mastectomy — (4)
- Halsted Radical Mastectomy — (5)

Radiotherapy.

- Dose 5000 - 6000 — (1)
- 200 cGy units per/day — (2)
- 5 days for 5 weeks. — (3)

Indication -

- Tumor Margin is Positive — (1)
- Inner Quadrant tumor — (2)
- Tumor size than 5cm — (3)

- Hormone therapy –
  - Tamoxifen — (1)
  - ER/PR examination — (2)
  - Metastasis — (3)
  - Chemotherapy — (4).

- chemotherapy –
  - Premenopausal — (1)
  - cyclophosphamide — (2)
  - oophorectomy — (3).

## Anatomy

Position - 2nd - 6th Rib vertically

Nipple - 4th Intercostal space.

Areola - Black colour

Quadrants - Right and left
Right and left

congenital diseases -

- Amazia - Breast Absence - (1)
- Polymazia - Breast Accessory - (2)
- Atheliа - Absence of Nipple - (3)
- Supernumering - Accessory Nipple - (4)
- Micromastia - Small Breast - (5)

- स्तनशिरा - (1)
- विवृता - (2)
- प्राचीर - (3)
- सूतानी - (4)
- गाविनी - (5)
- सदृग्धे - (6)
- विद्रधि - (7)
- सूक्ष्म वक्षा - (8).

- Treatment –

— दवा except उपचार — (1)
— पालन should be avoid — (2)
— Avoid Breast feeding — (3)

# Diseases of chest

- chest Injuries — (1)
- Pleural effusion — (2)
- Pleurisy — (3)
- Lung Abscess — (4)
- Lung cancer — (5)

**Chest Injuries** - Almost - 80% — (1)
- wounds — 10% — (2)

**Types** -
- closed — (1)
- open — (2).

**Causes** -
- Road traffic — (1)
- Industrial Accidents — (2)
- Assault Blunt objects — (3)
- Fall from Height — (4)
- Crush Injuries — (5)
- Gunshot Injury. — (6)

- Simple Rib fracture — (1)
- Sternal fracture — (2)
- Flail chest — (3)
- Stone in chest — (4)
- Contusion of lungs — (5)
- Pneumothorax — (6)
- Haemothorax. — (7)
- Trachea Injury — (8)

(1) <u>Simple rib fracture</u>

- Single or Multiple — (1)
- Rarely occurs — (2)
- Elders. — (3)
- Costal Angel — (4)
- Difficulty in Breathing — (5)
- Pain during Breathing — (6)
- Chest X Ray — (7).

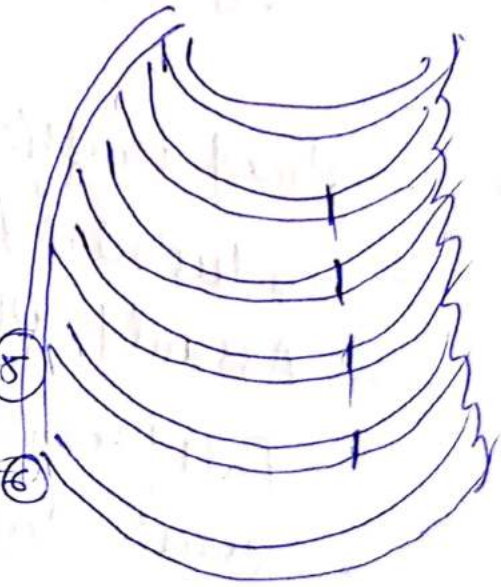

## Sternal fractures.-

- Steering wheel Injury — ①
- occurs at sternal Angle — ②
- localised swelling — ③
- tenderness — ④
- displaced fracture — ⑤

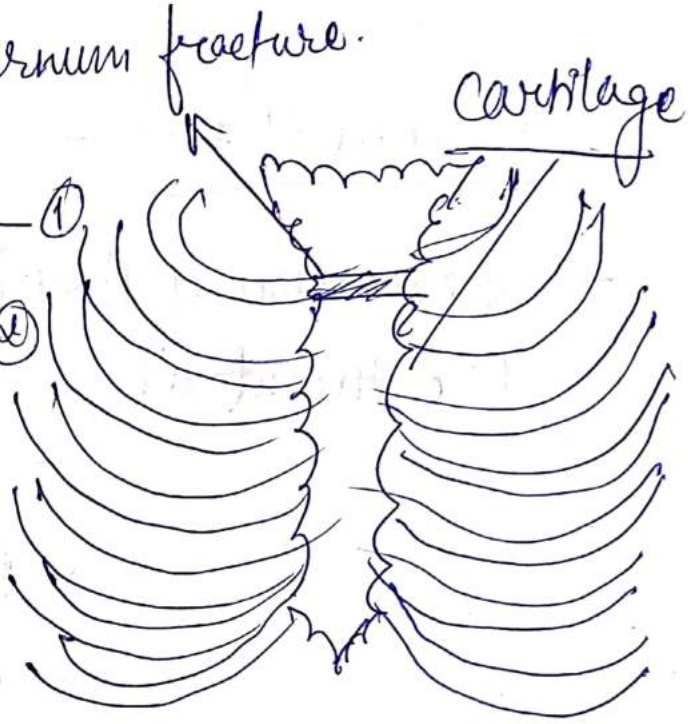


## Flail chest -

- Defined as fracture of 04 ribs — ①
- Inspiration — Moves Inwards — ②
- expiration — Moves outwards. — ③
- Surgical stabilization — ④
- IcT drainage — ⑤
- Antibiotics. — ⑥
- Bronchodilators. — ⑦

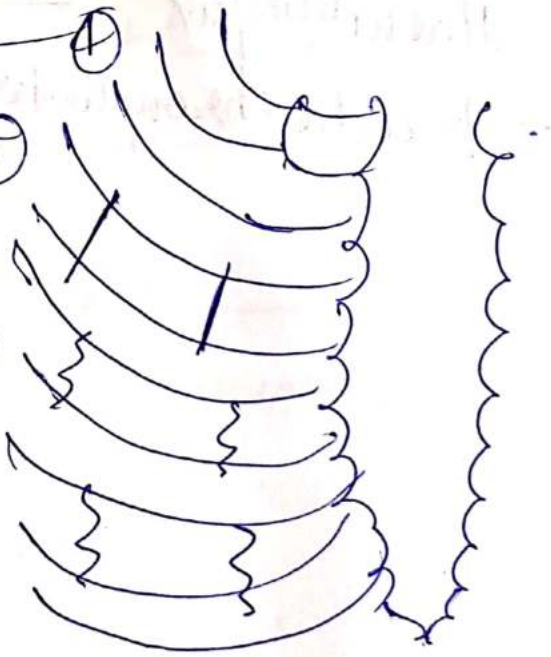

- Stove in chest -

- Depression of Portion of chest wall.
- Treatment as - Surgical
  - stabilization
  - Osteofixation.
  - Open Reduction

- Contusion of lung -

- Deceleration Injury — (1)
- capillary disruption — (2)
- Interstitial Haemorrhage — (3)
- Haemoptysis — (4)
- tracheobronchial secretions — (5).

## Pneumothorax –

- Presence of Air b/w Layers of Pleura — (1)
- Most common cause of respiratory Insufficiency — (2)
- Rib fracture — (3)
- subcutaneous emphysema — (4)
- Open — (5)
- closed — (6)
- tension — (7)

- **Features** — Dyspnea — (1)
  - pain — (2)
  - shock — (3)
  - Cyanosis — (4)
  - Hyperresonant — (5)
  - Breath Absence — (6).

**Hemothorax** — Pleural cavity Blood. — (1)
- Injury in Internal Mammary gland — (2)
- pain in chest
- difficulty in breathing

Treatment — Tet Insertion

- diagram –

# Pleural Effusion

Accumulation of fluid in pleural cavity in which is known as pleural effusion.

factors -

- Types — (1)
- Causes — (2)
- clinical features — (3)
- Investigations — (4)
- Treatment — (5)

Types - Transudate — (1)
— exudate — (2)

Transudate - excessive production of pleural fluid
- Re-absorption capacity is Reduced.

exudates - Pleura is damaged by trauma. — (1)
- Infection — (2)
- Malignancy — (3)

- Other types -

- Hydrothorax — (1)
- Pyothorax — (2)
- Chyle — (3)
- Haemothorax — (4)
- Pneumothorax — (5)

• Causes. -

- Trauma — (1)
- Bacterial pneumonia — (2)
- Tuberculosis — (3)
- congestive cardiac failure — (4)
- Pulmonary Infarction — (5)

• Clinical features -

- Breathlessness — (1)
- Chest Movement decreased — (2)
- Percussion — (3)
- Asculatation — (4)
- Massive effusion — (5)

## Investigations -

- X-Ray of chest PA — ①
- Pleural Aspiration — ②

## Treatment -

- Treat the cause — ①
- Antibiotics — ②
- Thoracocentesis — ③

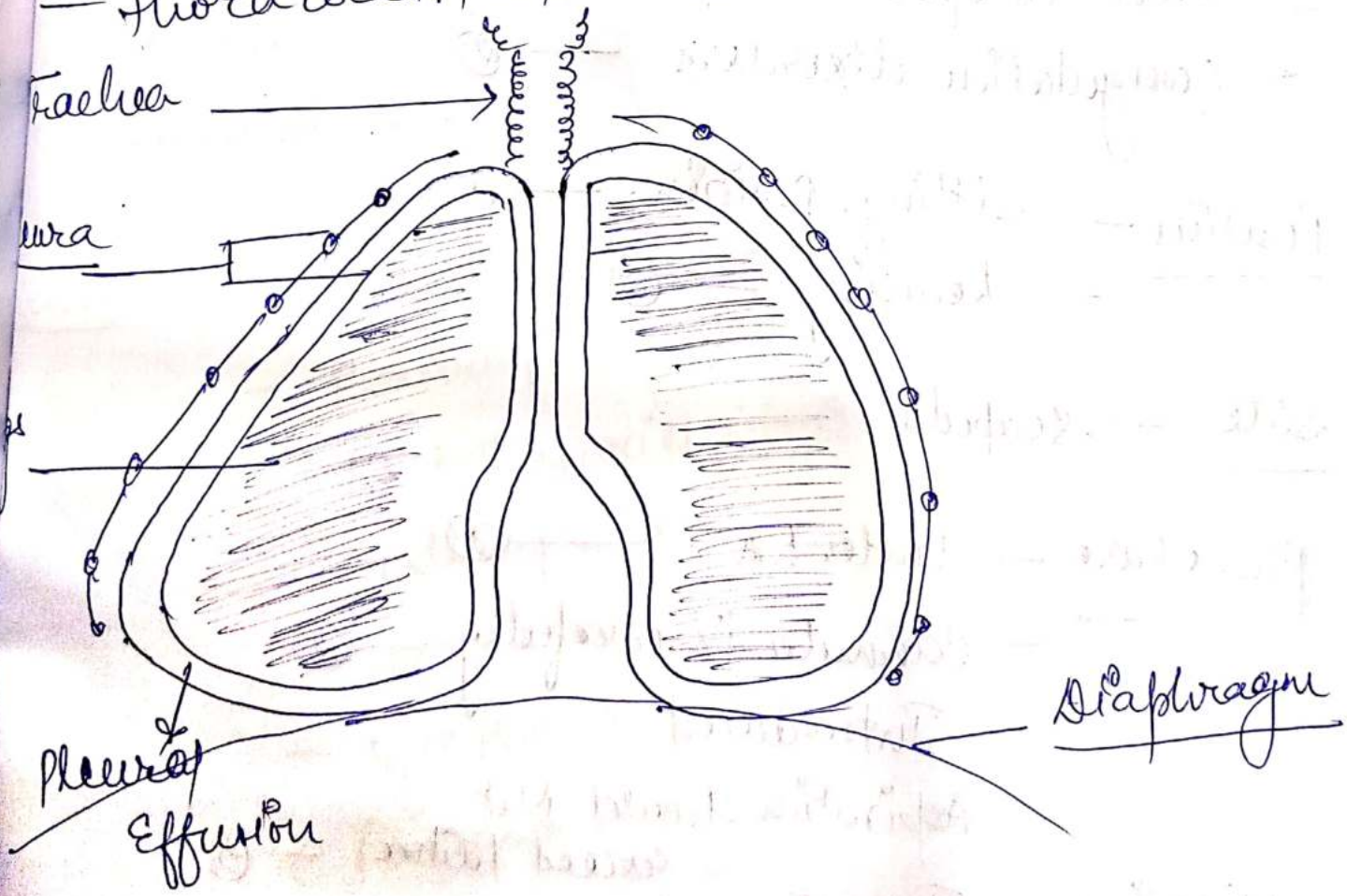

# • Pleural tap •

- Invasive procedure to Remove fluid

- **Factors** -
  - Pleural effusion — ①
  - Empyema thoracis — ②

  ] Indications

- **contra - Indications** -
  - Non-co-operative patients — ①
  - Coagulation disorders — ②

- **Position** - sitting position. — ①
  - Leaning — ②

- **Site** - Scapula.

- **Procedure** - Under LA. — ①
  - Cannula is carefully Introduced — ②
  - Aspiration should Not exceed 1 litre — ③

- **complications** - Infection — ①
  - Bloody tap — ②
  - Sudden vagal shock — ①
  - Dry tap — ②

# Pleurisy (फुफ्फुस आवरण शोथ) (pleuritis)

Def – Inflammation of tissues that line the lungs and chest cavity.

Factors –

Causes — ①
Clinical features — ②
Investigations — ③
Treatment — ④

Causes – Viral Infections — ①
– Bacterial Infections — ②
– Chest Injuries — ③
– Cardiac problems — ④
– Lung cancer — ⑤
– Lymphoma — ⑥
– Pneumothorax — ⑦

- Clinical features -

- Sudden sharp — (1)
- Stabbing — (2)
- Burning — (3)
- Breathing — (4)
- Coughing — (5)
- Sneezing — (6)
- Pleural friction rub — (7)

- Investigations -

- chest x-ray — (1)
- Blood tests — (2)

- Treatment -

- Treat cause — (1)
- Bed Rest — (2)
- Anti-Inflammatory — (3)
- Codein — (4)
- Thoracocentesis — (5)

# Lung Abscess (फुफ्फुस विद्रधि)

It's type of liquefactive Necrosis of lung tissue

Factors –

Primary (Types) — ①
Causes — ②
Causative organisms — ③
Signs and symptoms — ④
Investigations — ⑤
Treatment — ⑥

– Necrotic debris
– cavity formation (2cm)

Types –

– Primary — ① 60%
– Secondary — ② 40%

– Primary – Lung Parenchymal Process. — ①
– Secondary – Vascular Emboli — ②.

- Causes. –

  - Aspiration of oropharyngeal — (1)
  - Septic Emboli — (2)
  - Bronchial obstruction — (3)
  - Necrotizing Pneumonia — (4)
  - vasculitis — (5)

- Causative organisms –

  - Anaerobic Bacteria — (1)
  - Micro aerophilic — (2)
  - Aerobic Bacteria — (3)
  - Fungi — (4).

- Signs and symptoms.

  - cough — (1)
  - fever. — (2)
  - Night sweats — (3)
  - pleural Pain — (4)
  - Lethargy — (5)
  - Dental Decay — (6).

## Investigations -

- Raised ESR — (1)
- optic Bronchoscopy — (2)
- CT scan — (3)
- Trans bronchial Aspiration — (4)

## Treatment -

Acute conditions — (1)
Antibiotics — (2)
- pulmonary physiotherapy — (3)
- Postural drainage — (4)

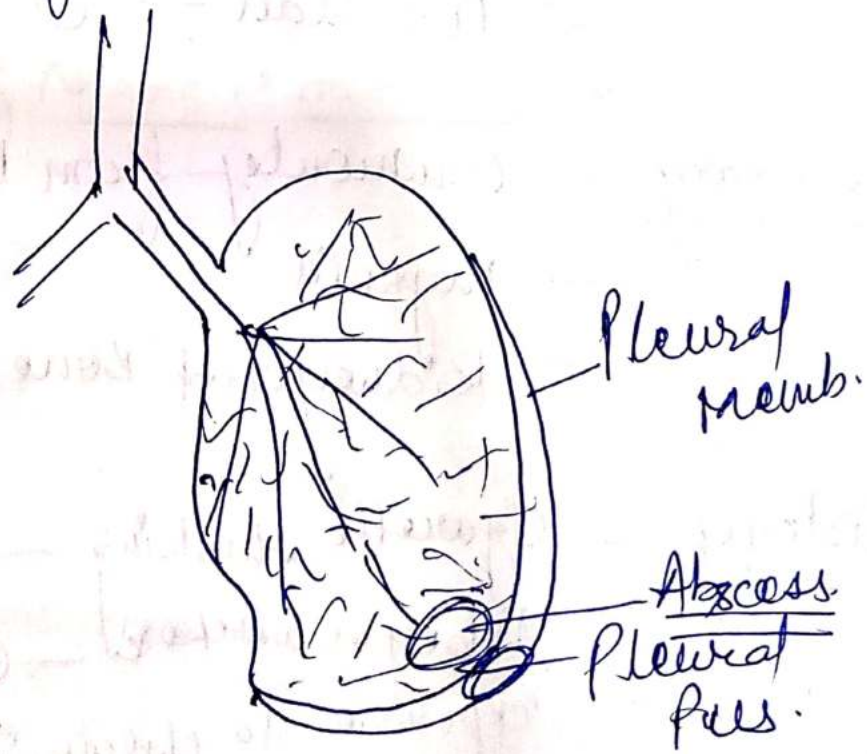

(CA). Lung Cancer (फुफ्फुस अर्बुद)

- A cancer that begins in the lungs and Most often occurs in people who smoke.

• Factors :

- Primary — (1) — initial start at lungs
- Secondary — (2) } Types → Spreading

- Primary - Evaluted by bronchoscope — (1)
  - CT scan — (2)
  - PET scan — (3)
    Positron emission tomography.

- Secondary - commonly from Breast
  - thyroid
  - Kidney and Bones.

• Aetiology - cigarette smoking — (1)
  - Asbestos workers — (2)
  - exposure to chromium — (3)
  - Gas and shoot — (4)

## Microscopic Varieties —

- Squamous cell CA — (1)
- Adeno Carcinoma — (2)
- Large cell CA — (3)
- Anaplastic CA — (4)
- Bronchio — Alveolar CA — (5)

## Clinical features —

- Persistent cough — (1)
- Loss of Appetite — (2)
- Haemoptysis — (3)
- Dyspnoea — (4)
- Clubbing — (5)
- Hoarseness — (6)
- Dysphagia — (7)

## TNM classification —

$T_4$ — Tumor Invasion

- $T_0$ — No evidence
- $T_1$ — Tumor less
- $T_2$ — Tumor More
- $T_3$ — direct extension

- Investigations -
  - Chest X-Ray
  - Cytological
  - Percutaneous Biopsy
  - Bronchoscopy
  - CT scan

- Treatment -
  - Surgery — (1)
  - Radiotherapy — (2)
  - Chemotherapy — (3)
  - Laser therapy — (4).

# गुल्म रोग (Nodule/Mass)

— हृदय अन्तरे ग्रंथि संचारी यदी वा अचल: ॥
— स्व गुल्म इति कीर्तित: ।

— गुल्म Nature — vitiated वायु — ①
— Any site — ②
— Large Appearance — ③
— clustre — ④

— Location of गुल्म — Coverall of Quadrants of Abdomen.

— पंच गुल्म त्रया नृणां पार्श्वे — (Susrutt 42/5).

— दक्षिण पार्श्व — ①
— वाम पार्श्व — ②
— हृदय — ③
— नाभि — ④
— बस्ति — ⑤

- Types – वातज — ①
  - पित्तज — ②
  - कफज — ③
  - सन्निपातज — ④
  - रक्तज — ⑤

- पूर्वरूप – विण्मूत्र — ①
  - अतीपो — ②
  - दोषोद्भवे — ③
  - सौहित्य — ④
  - विकृतान्न — ⑤

- Malaise — ①
- weak digestion — ②
- obstruction — ③
- Inability — ④
- Food Dislike — ⑤
- Eructations — ⑥

- वातज गुल्म लक्षण –
  - Abdominal Pain — ①
  - Dryness of Mouth — ②
  - Suppression — ③
  - digestion — ④.

पित्तज गुण — Perspiration — (1)
— ज्वर — (2)
— दाहः — (3)
— रक्त दाहः — (4)
— तृष्णा — (5)
— Flushing — (6)
— कटु रस in मुख — (7)

कफज गुण — आटाट dislike — (1)
— श्रमः — (2)
— क्लमः — (3)
— छर्दि — (4)
— Salivation — (5)
— Sweet taste (मधुर) — (6)

रक्तज गुण — Same features like पित्तज गुण — (1)
— ज्वर — (1) अंगमर्द — (6)
— दाहः — (2)
— छर्दि — (3)
— तृष्णा — (4)
— वेपन — (5)

## अवस्था अनुसार गुल्म

- आमावस्था — गुरुत्वा
  - Hard
  - Muscles fixed (पेशी)

- पच्यामान वस्था — दाहः — ①
  - शोफ — ②
  - कण्डू — ③
  - ज्वर — ④
  - ज्वर — ⑤
  - अग्निदृ — ⑥

- पक्वावस्था — दाहः — ①
  - Bluish red — ②
  - अतिवेदन — ③
  - ज्वर — ④
  - छर्दि — ⑤
  - भ्रमः — ⑥

साध्य/असाध्यत — साध्य — एकदोषज — ①
- कृच्छ्रसाध्य — द्विदोषज — ②
- असाध्य — सन्निपातज — ③

## - वातज गुल्म चिकित्सा -

- स्नेहन — (1)
- स्वेदन — (2)
- स्नेहपान — (3)
- विरेचन — (4)
- बस्ति — (5)
- रक्तमोक्षण — (6)
- चित्रकादी घृत — (7)
- हिंग्वादी घृत — (8)

## - पित्तज गुल्म चिकित्सा -

- स्नेहपान — (1)
- विरेचन — (2)
- निरूह बस्ति — (3)
- तरुणमुलादी घृत — (4)

## - कफज गुल्म चिकित्सा

- स्नेहपान — (1)
- अभ्यास — (2)
- विरेचन — (3)
- तीक्ष्ण — (4)
- रक्तमोक्षण — (5)

## रक्तज गुल्म चिकित्सा -

- स्नेहन — (1)
- स्वेदन — (2)
- घृतपान — (3)
- रक्तप्रदर चिकित्सा — (4).

- रक्तमोक्षण — (1)
- धूती यंत्र — (2)
- क्षार — (3)
- अग्निकर्म — (4)

- General चिकित्सा -
  - क्षार अवलेह — (1)
  - दधीका घृत — (2)
  - हिंगादी घृत — (3)
  - जंगल मांस रस — (4).

# शूल व्याधि (Abdominal colic)

निरुक्ति - In this condition — Pt feels severe pain.

निदान - अजीर्ण — ①
- वातमूत्र पुरीषाणां — ②
- अध्यशना — ③
- विरुद्ध अन्न सेवन — ④
- पानीय — ⑤
- विरुद्धा — ⑥

Types - वातज — ①
- पित्तज — ②
- कफज — ③
- सन्निपातज — ④

वातज शूल - स्तब्धता — ① - वातमूत्र — ④
- शूल तीव्र — ② - पुरीषाणि — ⑤
- निरुद्ध — ③

② पित्तज — तृष्णा —— ①
— दाहः —— ②
— मूर्छा —— ③
— Intoxication —— ④
— रीतकाकाभो —— ⑤

③ कफज — Nausea
— गुरुगात्रता —— ①
— excessive fullness —— ②
of Abdomen

④ सन्निपातज — त्रिदोषज लक्षण

चिकित्सा —
— वातज शूल चिकित्सा —
— स्वेदन — पयासा —— ①
— Diet — त्रिवृता —— ②
— Drinks — सुरा —— ①
— सुक्त —— ②
— घृत —— ③

## पित्तज शूल चिकित्सा –

- Purgation therapy — (1)
- Diet —
  - Jaggery
  - शाली Rice
  - Barley
  - दूध / क्षीर
  - Palm fruits / फल

## कफज शूल चिकित्सा –

- Emesis — (1)
- पिप्पली — (2)
- वचा चूर्ण — (3)
- पिप्पली भस्म — (4)
- Dry fomentation — (5)

# - Acute Abdomen -

- Acute Abdomen is a condition that demands urgent attention and treatment.

## - Factors -

- Causes — ①
- Visceral Pain — ②
- Nature of Pain — ③
- Abdominal distension — ④
- Tenderness — ⑤
- Investigations — ⑥
- Treatment — ⑦

① Causes. - Right Hypochondrium -

- Acute cholecystitis — ①
- Acute cholangitis — ②
- Hepatitis — ③
- Hyper Acidity — ④
- duodenal ulcer — ⑤

Epigastrium — Acute Hyper Acidity — ①
— Acute pancreatitis — ②
— Perforated duodenal — ③
— Acute hepatitis — ④

Left Hypochondrium —

— Acute Hyper Acidity — ①
— Acute Pancreatitis — ②
— Splenic Infarct — ③

Hypogastrium —

— Acute cystitis — ①
— Acute Congestive — ②
— Acute Meckel's diverticulitis — ③
— Uterine fibroid — ④

Right Lumbar — Right Renal Pathology — ①
— CA of Ascending colon — ②

Right iliac fossa

- Acute Appendicitis
- Acute Meckles diverticulitis
- Torsion of testis
- Ureteric colic

Left iliac fossa

- Acute diverticulitis
- Torsion of testis
- Ureteric colic

| RHypo. | Epi | Left Hypo. |
|---|---|---|
| R Iliac f. | Hypog. | L Iliac fo |
| RL. | Umbilicus | L lumb |

- Visceral Pain

- epigastrium — ①
- umbilicus — ②
- Hypogastrium — ③
- epigastrium — ④
- groin — ⑤
- umbilicus — ⑥.

- Nature of Pain —

- continous pain — ①
- Episodic — ②
- colicky — ③

- Pain relieving factor —
- Associated with fever — ④
- Pain aggravation — ⑤
- Reffered Pain — ⑥

## Tenderness —

- Right upper Quadrant — (1)
- Right lower Quadrant — (2)
- Hypogastrium — (3)
- Epigastrium — (4)
- Left upper Quadrant — (5)
- Left lower Quadrant — (6)

## Investigation —

- Routine blood checkup — (1)
- Plain X-Ray — (2)
- Endoscopy — (3)
- Stool Examination — (4)
- USG — (5)
- CT Scan — (6).

## Treatment —

- Medical treatment — (1)
- Surgical treatment — (2)
- Laproscopy — (3).

# Ascitis

It is a pathological condition of fluid Peritoneal cavity.

Ref - Surgery / शल्यतंत्र

Factors -

- Types — ①
- clinical features — ②
- Signs — ③
- Investigation — ④
- Treatment — ⑤

Types -
- Mild — ①
- Moderate — ②
- Severe — ③

- Mild - 150 ml — ①
- Moderate - 1500 - 2000 ml — ②
- Severe - 2000 ml — ③

Protein -
- Transudate protein — ①
- Exudate Protein — ②.

- SAAG - Serum Ascites Albumin gradient.
- Portal Hypertension — Causes $Na^+$ Retention.
  - Increase Hydrostatic Pressure

- Clinical features -
  - Specific features — (1)
  - Abdominal distension — (2)
  - Respiratory embarrasment — (3)
  - Right sided pleural effusion — (4)

- Signs -
  - Mild — (1)
  - Moderate — (2)
  - Severe — (3)

- Investigations - USG Abdomen.
  - Ascite tap.

- Treatment - Spironolactone — (1)
  - Paracentesis Abdomin's — (2)
  - Peritoneum Puncture — (3).

# Intestinal obstruction

- when Intestinal contents are obstructed distally is called Intestinal obstruction.

- Surgery / शल्यतंत्र

Factors -

- classification
- Pathology
- Symptoms / clinical features
- Investigations
- Treatment.

Classification - Depend of Nature of obstruction — ①
- Depend of obstruction cause — ②
- Depend on Severity of Infection — ③
- Depend on Blood supply — ④.

— Depend on Degree of Block.

① Depend of Nature of obstruction —

— Dynamic obstruction — ①
— Adynamic obstruction — ②

② Depend on cause of obstruction.

— lumen of gut — ①
— Wall of gut — ②
— outside wall of gut — ③

③ Depend on severity of Infection

— Acute — ①
— chronic — ②

④ Depend on Blood supply

— simple obstruction — ① — Closed obstruction. —
— strangulated obstruction. — ②

Depend on Degree of Block.

- Partial Block — ①
- complete Block — ②.

Pathology —

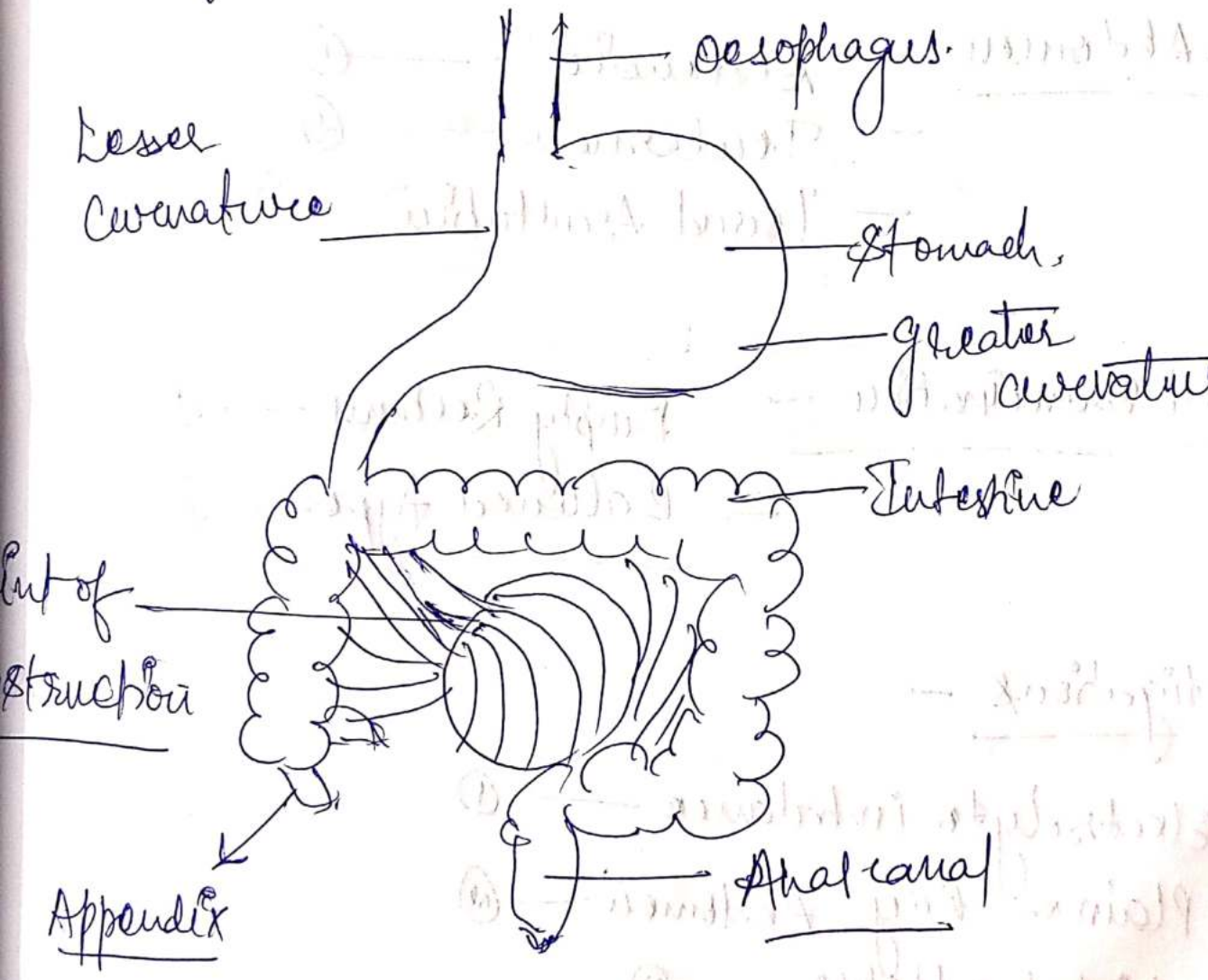


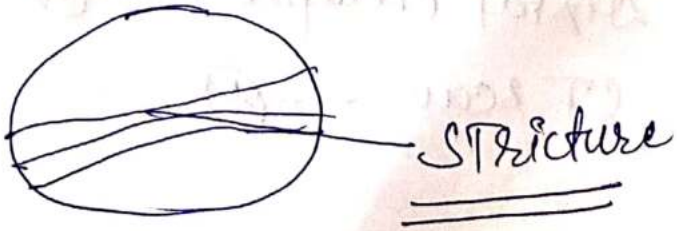

- Symptoms.–
  - Pain in Abdomen —— (1)
  - Vomiting —— (2)
  - Abdominal distension —— (3)
  - Constipation —— (4).

- Per Abdomen – Distension —— (1)
  - Tenderness —— (2)
  - Bowel Ascultation —— (3)

- Rectal Examination – Empty Rectum —— (1)
  - Ballooned type —— (2)

- Investigations –
  - Electrolyte imbalance —— (1)
  - Plain x-Ray Abdomen —— (2)
  - Distal collapse —— (3)
  - CT scan —— (4).

## Management —

- Nasogastric Aspiration — (1)
- fluids — (2)
- Antibiotics — (3)
- Drugs — (4)
- Blood transfusion — (5)
- IEV. — (6).

## Surgical treatment

- Simple obstruction Surgery — (1)
- Small Intestine obstruction Surgery — (2)

# Peritonitis

- Inflammation of Peritoneum
- through - septic Activity — (1)
  - Bacterial Activity — (2)
  - Acute/Chronic — (3)

Factors - Ref - Surgery / शल्य तंत्र

- causes — (1)
- clinical features — (2)
- Investigations — (3)
- Treatment — (4)

Causes. - Primary cause — (1)
- secondary cause — (2)
- Tertiary cause — (3)

(1) Primary cause - Bacterial Cause
- Pneumococci — (1)
- streptococcus — (2)
- E coli — (3)
- TB. Peritonitis — (4).

- Secondary Peritonitis –
  - Local extension –
    - Acute cholecystitis –
    - Acute Appendicitis –

- causative Agents –
  - E-coli – (70%) –
  - streptococcus – (2)

- Perforation – Perforated duodenum – (1)
  - Perforated Meckel's diverticulum – (2).
  - Perforated ulcer – (3).

- Professional cause –
  - Improper sterilization – (1)
  - Improper fumigation – (2)
  - unsterile surgery – (3).

- Parturition Peritonitis –

  – Related to after Pregnancy and delivery.

- Tertiary Peritonitis –

  – Recurrent Intra Abdominal Infection — ①
  – Severe condition Leads to MODS — ②
  – Organisms — ③.

- Chemical Peritonitis — ①
- Bacterial Peritonitis — ②
- Initially chemical Induced — ③.

Clinical features –

– Abdominal Pain — ①
– Vomiting — ②
– irritation — ③
– Fever — ④
– cough — ⑤
– tenderness — ⑥.
– Bowel sound affected — ⑦
– Abdominal distension — ⑧.

- **Investigation** -
  - Plain X-Ray — (1)
  - Abdominal USG — (2)
  - Abdominal CT — (3)
  - Diagnostic Laparoscopy — (4).

- **Treatment** -
  - systemic antibiotics — (1)
  - Resuscitation — (2)
  - Electrolytic Management — (3)
  - Percutaneous USG — (4)
  - Laparotomy — (5)
  - ICU care — (6).

- **Surgery** — Appendicectomy — (1)
  - perforation closure — (2)
  - Resection of gangrene — (3).

# Perforation of Peptic Ulcer (PPU)

untreated ulcer has burned through the Mucosal wall of GIT.

Ref - [illegible] / surgery

Factors -

- Stages — ①
- Investigations — ②
- Management — ③

Stages - Stage of chemical Peritonitis (2-4 Hrs)

- Acute pain in epigastrium Region — ①
- coffee ground vomiting — ②
- Fever — ③
- Tenderness — ④
- Rigidity — ⑤
- Bowel sounds Absents — ⑥

(2) Stage of Reaction (3-6 Hrs)

- Tachycardia — (1)
- Hypotension — (2)
- dehydration — (3)
- Abdominal distension — (4)
- Guarding — (5)
- Rigidity — (6).

(3) Stage of Bacterial Peritonitis (12 Hrs)

- illness — (1)
- sunken eyes — (2)
- Rapid breath — (3)
- Hypovolaemic shock — (4)
- Septic shock — (5)
- Abdominal distension — (6)
- Rigidity — (7)
- tenderness — (8).

## Investigations -

- Plain X-Ray — (1)
- USG — (2)
- CT-Scan — (3)
- Aspiration of Peritoneal cavity — (4).

## Treatment -

- Aspiration. — (1)
- Fluids. — (2)
- Drugs. — (3)
- Inj- Ampicillin. 500mg — (4)
- Inj. Genta - 80mg — (5)
- Inj. Metronidazole - 500mg — (6)

• diagram –

sophagus. diseases.

# GERD. Gastro oesophageal Reflux Diseases.

(Reflux Oesophagitis)

(Regurgitation)

- Regurgitation of gastric contents into oesophagus called GERD. → Disease of oesophagus

Factors –

- Associated diseases — ①
- Types — ②
- Pathology — ③
- Traid — ④
- clinical features — ⑤
- Investigation — ⑥
- Treatment — ⑦

Other factors – obesity — ①
- Smoking — ②
- Excessive eating — ③
- Alcohol — ④
- Badly Performed operations — ⑤

- **Associated diseases** –
  - Sliding Hernia — ①
  - Reflux-oesophagitis — ②

- **Types** –
  - Primary — ①
  - Secondary — ②
  - Acute — ③
  - chronic — ④

- **Pathology** –

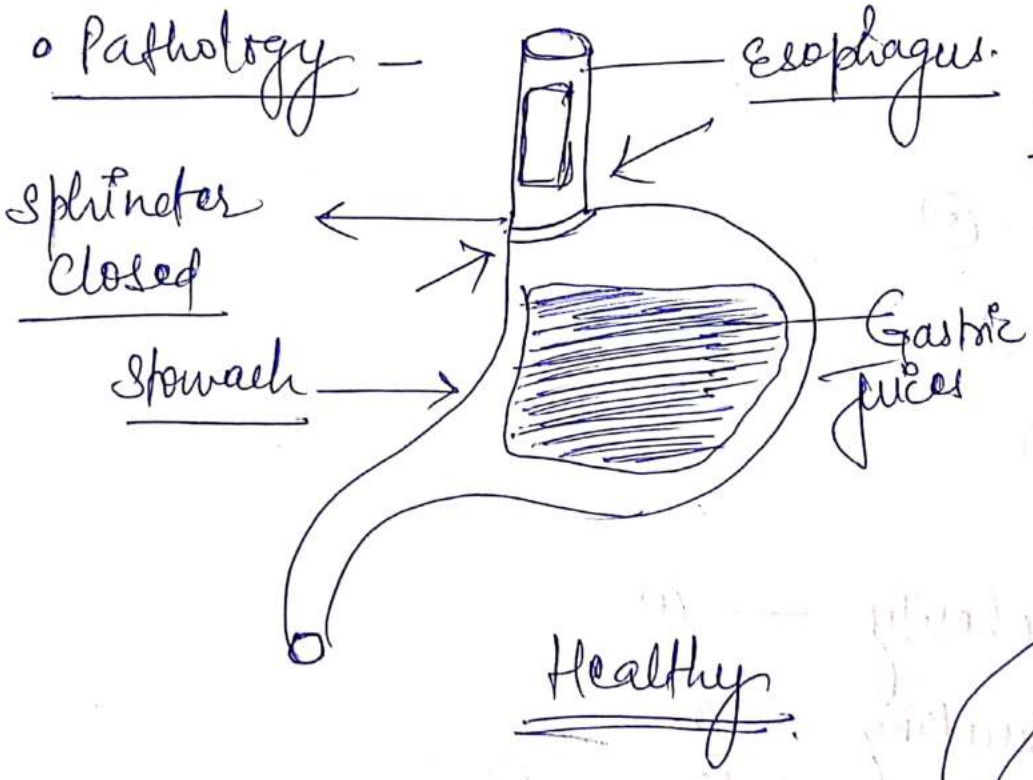


Healthy

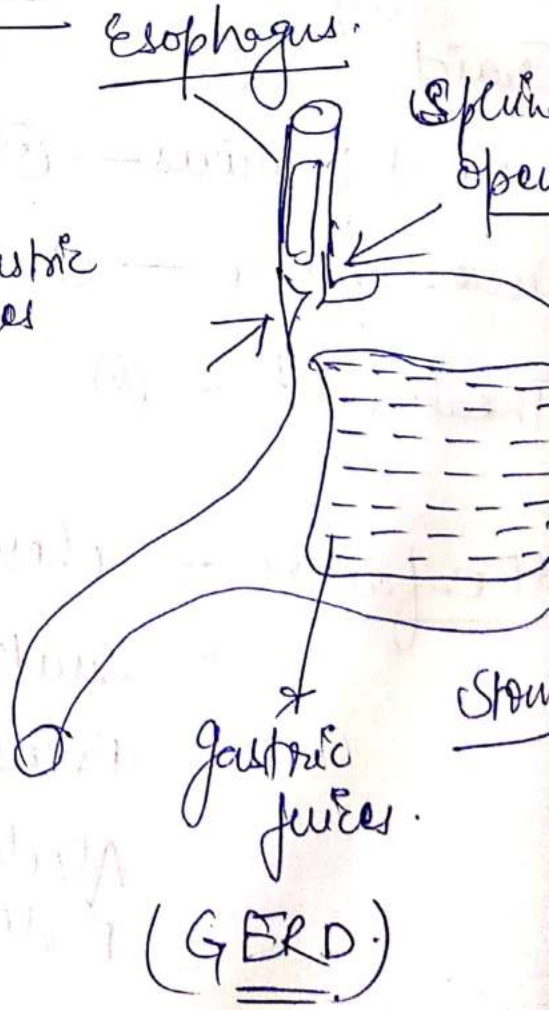


(GERD)

## Pathology —

- Acid Reflux. —— (1)
  ↓
- Produces Inflammation. —— (2)
  ↓
- Hyper Activity of Inflammation —— (3)
  ↓
- Produce Muscle Spasm —— (4)
  ↓
- Increase of Cardiac Angle —— (5)
  ↓
- due to this, Reflux increases. —— (6)
  ↓
- Causes GERD. —— (7).

## Triad —



- Clinical features -
  - Retro-sternal Pain — (1)
  - Dysphagia — (2)
  - Haemorrhage — (3)
  - Anaemia — (4)
  - Vomiting — (5)
  - Head ache — (6)
  - Sore Belching — (7).

- Investigation -
  - Barium swallow — (1)
  - Oesophagoscopy — (2)

- Treatment -
  - General treatment
    - Avoid spicy food — (1)
    - Alcohol — (2)
    - using Pillow — (3)
    - weight Reduction — (4)
    - Bed rest. — (5)

## Medical treatment –

- Antacids — ①
- Ranitidine — ②
- Omeprazole — ③
- Prokinetics — ④

Antacids
- Gremaffin
- Digene
- Pepcid
- Nimecoid (Ayurved)

## Contra Indicated drugs.

- Muscle Relaxant — ①
- Anti cholinergic drugs. — ②

## Surgical treatment –

- Mobilization — ①
- Abdominal oesophagus. — ②
- Narrowing of oesophageal Hiatus. — ③.

**Types of ARO.** –
- Nissen — ①
- Hill Posterior — ②
- Belsey Mark — ③

**Complications** –
- Barrett's oesophagus — ①
- Barrett's oesophagus → Adenocarcinoma. — ②
- Lower end oesophagus. — ③.

- Ayurvedic formulations -

— Madiphala Rasayana — (1)

— आमलकी चूर्ण — (2)

— खण्ड शर्करा — (3)

— लघु सूतशेखर रस — (4)

— Indukanta घृत — (5)

# Oesophageal Varices (अन्नवलिकागत) (सिरा ग्रन्थि)

- Abnormal veins in the lower part of the tube running from the throat to stomach.

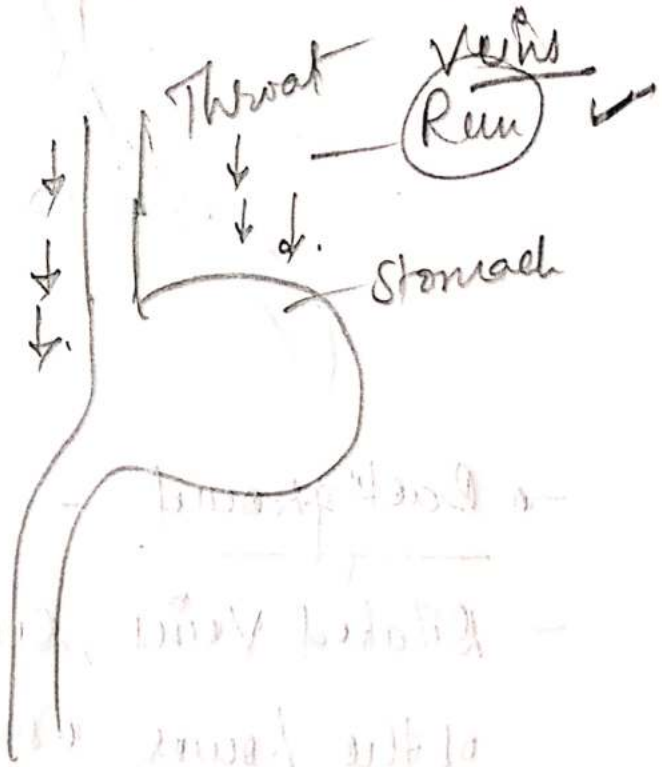


Factors —

- causes. —— ①
- Pathology —— ②
- Types —— ③
- clinical features —— ④
- Investigations —— ⑤
- Grading —— ⑥
- Treatment —— ⑦
- आयुर्वेद management —— ⑧

- Causes. — cirrhosis —— ①
  - Blood clot —— ②
  - Budd-chiari syndrome —— ③.

- Pathophysiology –

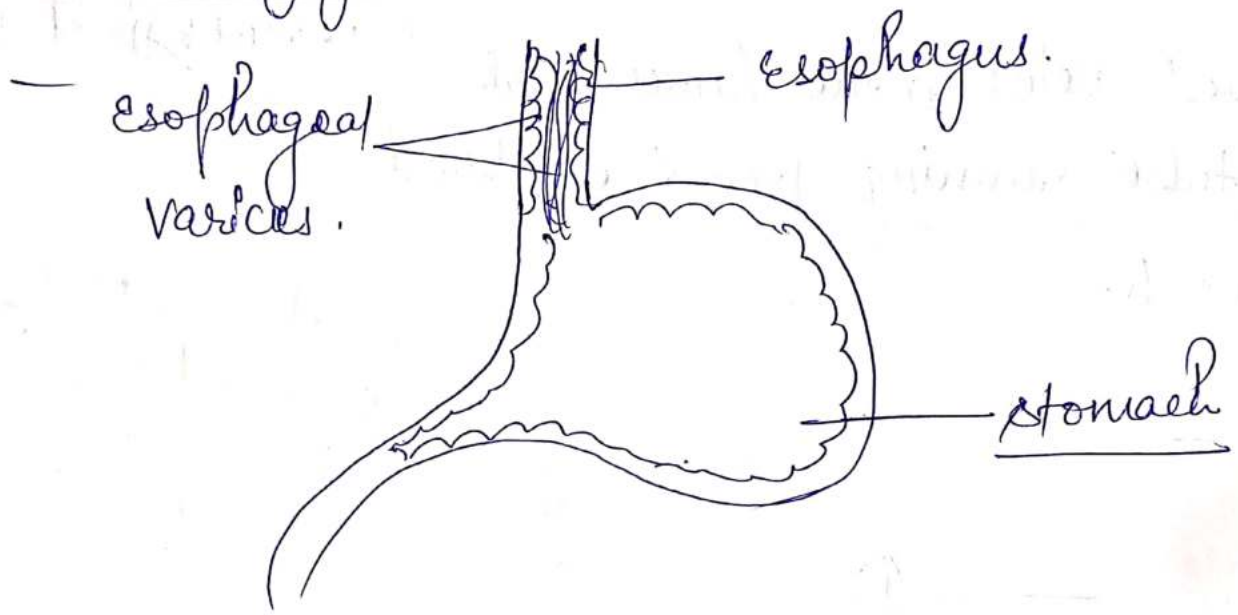


- Background –

– Dilated veins, develop within the lining of the lower esophagus. —— (1)

– Variceal Bleeding is most common complications. —— (2).

- Diagnosis

– upper endoscopy —— (1)

– Graded Based on size and Risk —— (2)

Types –

- Oesophageal (80%) — (1)
- Gastric (20%). — (2).

Clinical features –

- Vomitting — (1)
- Bloody stool — (2)
- Features of shock — (3)
- Light Headache — (4)
- Loss of consiousness. — (5)

Greading –

- Minimal — (1)
- Large — (2)
- Moderate — (3)
- Very Large — (4).

Minimal – without Laminal Prolapse — (1)

Large – with Laminal Prolapse — (2)

Moderate – with Laminal Prolapse — (3)

Very Large – with Laminal Prolapse — (4).

- Treatment –

– Emergency care is directed at stopping of Blood
– Beta (β) Blocker — (1)
– Blood Volume resuscitation — (2)
– Therapeutic endoscopy — (4)
– Oesophageal devascularization — (5)

- आयुर्वेद चिकित्सा –

– कोलगुड रस — (1)
– Tab Styplon — (2)
– कैशोर गुग्गुलु — (3)
– Tab – Pilex — (4)

# HERNIA

- Hernia is a Medical condition in which organ inside the Body.

Factors —

- causes.
- Types.
- Symptoms.

Causes. — weakened Muscles — (1)
— Straing — (2)
— Abdominal pain — (3)
— Inflammation — (4)
— Heavy cough — (5)
— constipation — (6)

Types. — Inguinal Hernia — (1)
— Femoral Hernia — (2)
— umblical Hernia — (3)
— Hiatus Hernia — (4).

# Hiatus Hernia :

— Abnormal Herniation of stomach in thorax

— Factors — Types. — (1)
— symptoms. — (2)
— Treatment — (3)

- Types — sliding Hernia — (1)
— Rolling Hernia — (2)
— Mixed Hernia — (3).

- Symptoms — Regurgitation — (1)
— Dysphagia — (2)
— Haematemesis — (3)
— Melaena — (4).

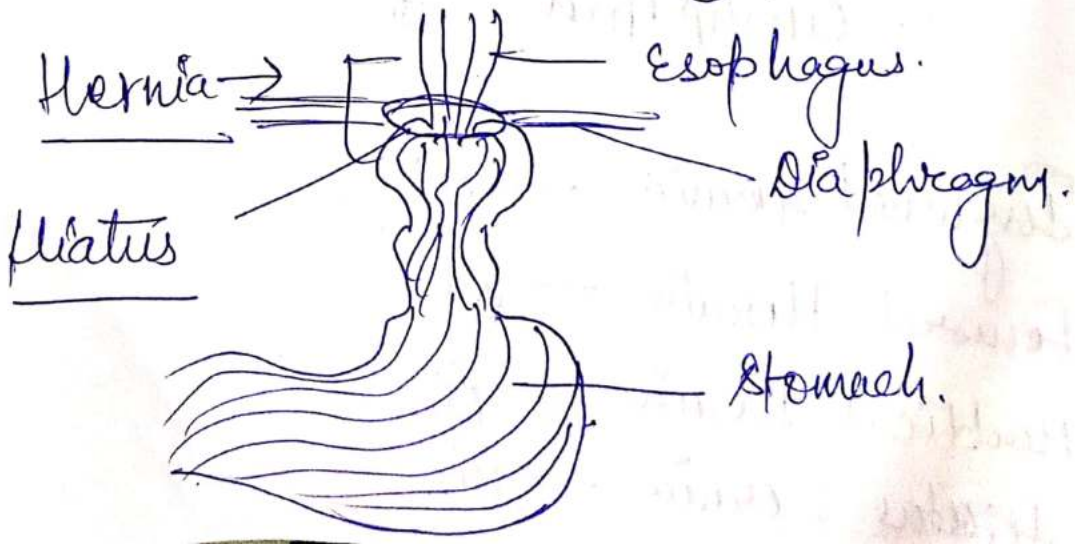

# Sliding Hernia

**Key points** – 2cm of Intra-Abdominal Oesophagus — ①
- Angle of His — ②
- Oesophago-cardiac Angle 45° — ③
- Mucosal fold — ④
- Intra-Abdominal Pressure — ⑤
- LOS function — ⑥.

**Causes** –

F – Fatty tissue — ①
A – Advancing Age — ②
T – Tumor of Lower Abdomen — ③

**Clinical features** –

- Asymptomatic
- GORD – Gastro-Oesophageal Reflux disease.

**Investigation** – Oesophagoscopy

- **Treatment** –

  - General — (1)
  - Conservative — (2)
  - Surgery — (3).

  - **General** – Diet control — (1)
    - Decreased Alcohol — (2)
    - weight Reduction — (3).

  - **Conservative** – Antacids — (1)
    - $H_2$ Blocker — (2)
    - Proton Pump Inhibitors — (3)
    - Gastric Reflux — (4)

  - **Surgery** – fundoplication — (1)
    - Hill's Repair — (2)
    - Nissen fundoplication — (3).

## Nissen fundoplication

- Reduction and Repair of Hernia

- Factors -

- Procedure — ①
- Complications — ②
- Advantages — ③

- Procedure - Mobilised by dividing short gastric Arteries — ①

- Fundus wrapped in front of oesophagus — ②
- using Non-Absorbable sutures.

Complications - Too tight Placentation — ①
- dysphagia occurs. — ②.

— Partial fundo plication

— Fundus suture side of oesophagus.

- Advantages. -

— Reduce size of Hernia — ①
— Creates Valve — ②
— Low. Recurrence — ③

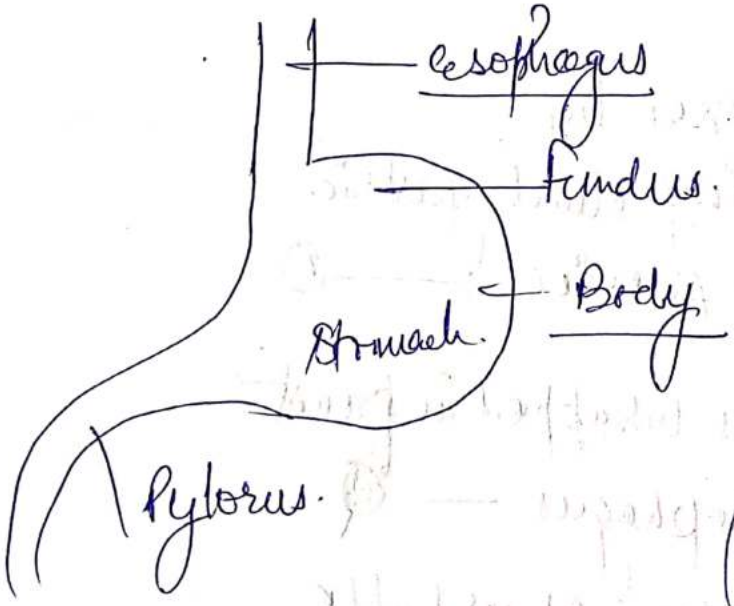


Normal Anatomy

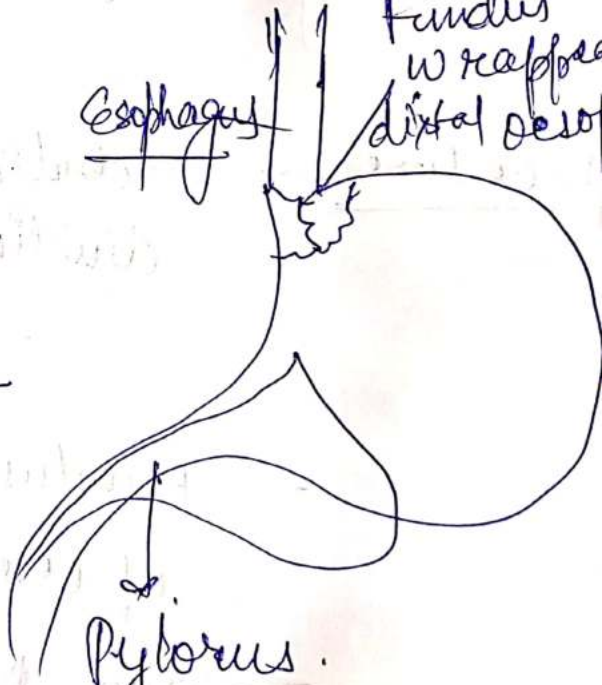


Fundoplication

# Rolling Hernia

It is also called as - Para- oesophageal Hiatus Hernia.

Less common.

Part of stomach pushes up through hole in the diaphragm :

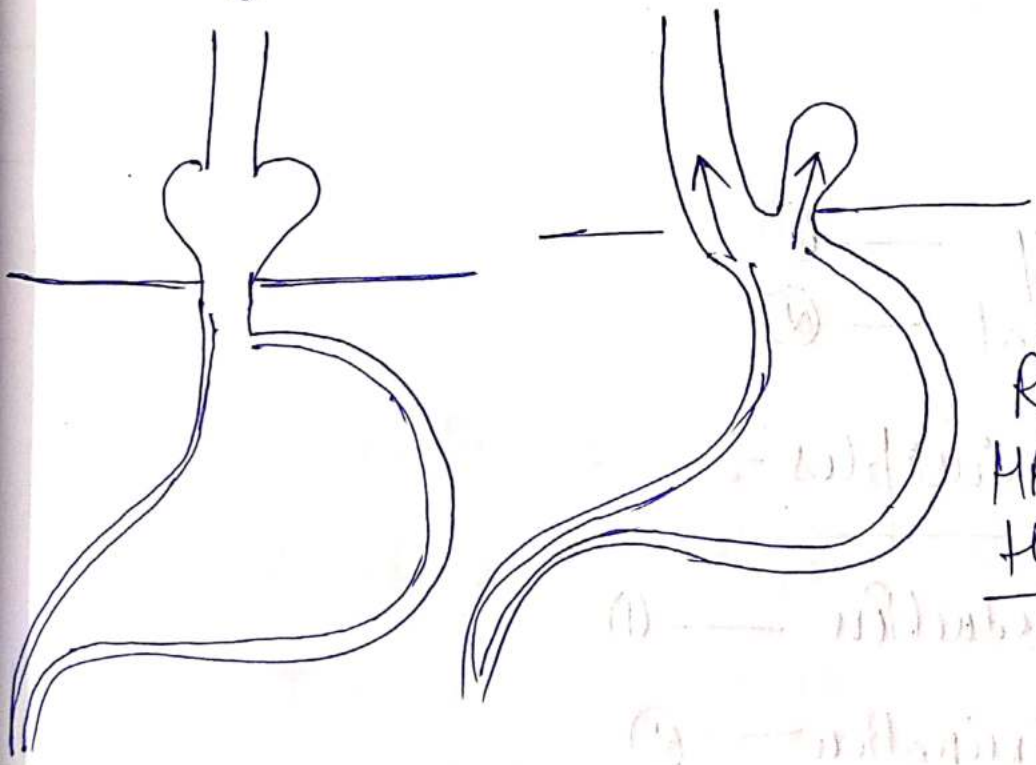

Rolling Hiatus Hernia

Factors - clinical features — ①
- Diagnosis — ②
- Treatment — ③
- complication — ④

- Clinical features -
  - Pain in Abdomen — (1)
  - Chest Pain. — (2)
  - Dysphagia — (3)
  - palpitation — (4)
  - Respiratory tract Infection — (5)
  - Ascultation — (6)

- Diagnosis -
  - chest X-Ray — (1)
  - Barium Meal — (2)

- Treatment Principles :-
  - Hernia Reduction — (1)
  - Sac elimination — (2)
  - Large opening Repair — (3)
  - Anti- Reflux operation — (4).

- Complications - gastric volvulus. — (1)

# Oesophagaal Perforation

- directly co-relates with the Hole in esophagus.

Factors —

- causes —— (1)
- symptoms —— (2)
- Signs —— (3)
- Investigations —— (4)
- treatment —— (5)

Causes. —

- Professional cause —— (1)
- Oesophagaal pathology —— (2)
- Trauma —— (3)
- Spontaneous. —— (4)
- previous surgery —— (5).

- ~~Causes~~ —
- Symptoms — Pain in chest — (1)
  - — Nausea — (2)
  - — Dyspnoea — (3)

— Signs — Hamman's sign — (1)
- — Fever — (2)
- — shock — (3)
- — Neck stiffness — (4).

- Investigations — Chest X-Ray — (1)
  - — Collapsed lung — (2).
  - — leak fluid — (3).

— Treatment — Thoracotomy — (1)
- — drain all pus — (2)
- — IV fluids — (3)
- — IV Antibiotics — (4).

# CA oesophagus (ग्रासनलिका अर्बुद)

- Esophageal cancer is cancer type.
- Initial start at the cell sites.
- In the cells that line the inside of esophagus.

- Two most common type —
  - Squamous cell carcinoma — (1)
  - Adeno-carcinoma — (2).

- Male : Female
  03 : 01

- Factors —
  - Aetiology — (1)
  - Sites — (2)
  - clinical features — (3)
  - spread — (4)
  - TNM classification — (5)
  - Investigations — (6)
  - Treatment — (7)

— Aetiology —

- Diet — (1)
- Heavy smoking — (2)
- Deficiency VIT-A — (3)
- Anaemia — (4)
- Oesophageal web — (5)
- Plummer Syndrome — (6)
- Reflux oesophagitis — (7)

• Sites — Middle — 1/3rd — 50% — (1)
— Upper — 1/3rd — 17% — (2)
— Lower — 1/3rd — 33%. — (3).

• Clinical features —

- Dysphagia — (1)
- Regurgitation — (2)
- Vomiting — (3)
- Loss of Appetite — (4)

- Spread -
  - Local spread — ①
  - Lymphatic spread — ②
  - Blood spread — ③

- Local spread - Left main Bronchus. — ①
  - Carcinoma upper — ②
  - Carcinoma Middle — ③
  - Oesophago-aortic fistula — ④.

- Lymphatic spread -
  - Upper Oesophagus — ①
  - Middle Oesophagus. — ②
  - Lower oesophagus — ③.

- Blood spread -
  - Enlarged Liver (Nodular).

## TNM classification –

- **Tumor** –
  - $T_0$ = No primary tumor — ①
  - $T_1$ – Invasion Lamina propria — ②
  - $T_2$ = Invasion Muscularis propria — ③
  - $T_3$ = Paraoesphageal Invasion — ④
  - $T_4$ = Invades structures — ⑤

- **Nodes**
  - $N_0$ – No regional lymph Nodes — ①
  - $N_1$ – 1 to 2 five Nodes — ②
  - $N_2$ – 3 to 6 five Nodes — ③
  - $N_3$ – 7 or more five Nodes — ④

- **Metastasis** – $M_0$ – No — ①
  - $M_1$ – yes — ②.

## Investigations –

- Oesophagoscopy with multiple biopsies —— ①

## Treatment

- Surgery – Radical oesophagectomy —— ①
- Radiotherapy – Dose is 6000. —— ②
- Chemotherapy – cisplatin and 5 FU. —— ③.

CORK screw oesophagus - (Achalasia)

- Rosary bead oesophagus  Cardiospasm

- Referred as - Rosary bead oesophagus.
- Diffuse oesophageal spasm. — (1)
- Reflecting Abnormal contractions — (2)
- compartmentalization. — (3)
- curling of oesophagus. — (4).

- clinical feature -
  - Difficulty in swallowing — (1)
  - chest Pain — (2)
  - Dysphagia — (3)
  - Nausea — (4)
  - Vomiting — (5).

- Difficult to Pass the food into stomach

# Congenital Oesophageal ATRESIA (COA)

(अन्नप्रणालिका संरोध)

- Congenital Oesophageal Atresia.
  Associated with Tracheo-Oesophageal Fistula
- Causes Oesophagus (Blind ended Pouch)
- 1 in 4500 Birth

Factors -

- Types — ①
- Anomalies — ②
- Clinical features — ③
- Management — ④

Types - Type I — 90% < Upper — ①, Lower — ②

- Type II — (8%) — Upper — ①
- Type III — (1-2%) — < Lower — ①, Upper — ②
- Type IV — (<1%) — < Upper — ①, Lower — ②.

— Anomalies

— V — Vertebral defects — ①
— A — Ano-rectal Malformation — ②
— C — cardiac defect — ③
— TE — Tracheo-oesophageal fistula — ④
— R — Radial Hypoplasia — ⑤

- Clinical features —

— saliva pooling — ①
— Regurgitation — ②
— coughing — ③
— Aspiration — ④
— cyanosis — ⑤
— Trachea-oesophageal fistula — ⑥

- Treatment — General — Antibiotics — catheter su
— IV Infusion
— Surgery — Right thoracotomy — ①
— Oesophagostomy — ②

# Achalasia cardiae / Cardiospasm

Achalasia — Failure of Relaxation.

Cardiospasm — Because of Severe spasm.

Factors -

- Aetiology — (1)
- clinical features — (2)
- Traid — (3)
- Investigation — (4)
- Treatment — (5)

Aetiology -

- Caused by trypanosoma cruzi. Chagas diseases.
- Stress — (2)
- emotional factors — (3)
- Vitamin $B_1$ deficiencies — (4)
- Incomplete Relaxation — (5)
- Peristalsis Absence — (6)
- Oesophagus dilated — (7)
- fermentation — (8).

— Clinical features

— Dysphagia — (1)
— Regurgitation — (2)
— weight loss — (3)
— Resp. tract Inf — (4)
— Heart Burn — (5)

• Triad —




• Investigation —

— Barium swallow — (1) (Bird Beak sign) (Rat tail sign)
— Oesophagoscopy — (2)

• Treatment — Medical — Calcium Antagonist
— Sublingual Nifedipi
— Mechanical dilatation — (4) — Inj Botulinum — (3)
— Surgery — (5)

# Plummer Vinson Syndrome

- Severe spasm of circular muscle fibres at cricopharyngeal sphincter level.
- Disorder marked by iron deficiency
- web like growth — in throat

- Also called — Paterson — Kelly syndrome

- Factors —
- Incidence — ①
- clinical features — ②
- Treatment — ③.

① Incidence — Females >40 years.
— Long standing iron def.

② Clinical features — cervical dysphagia — ①
— Features of Anaemia — ②
— Bald tongue — ③

## Treatment -

- Improve Anaemia — (1)
- Nutritional deficiency — (2)
- Regular dilatation — (3)

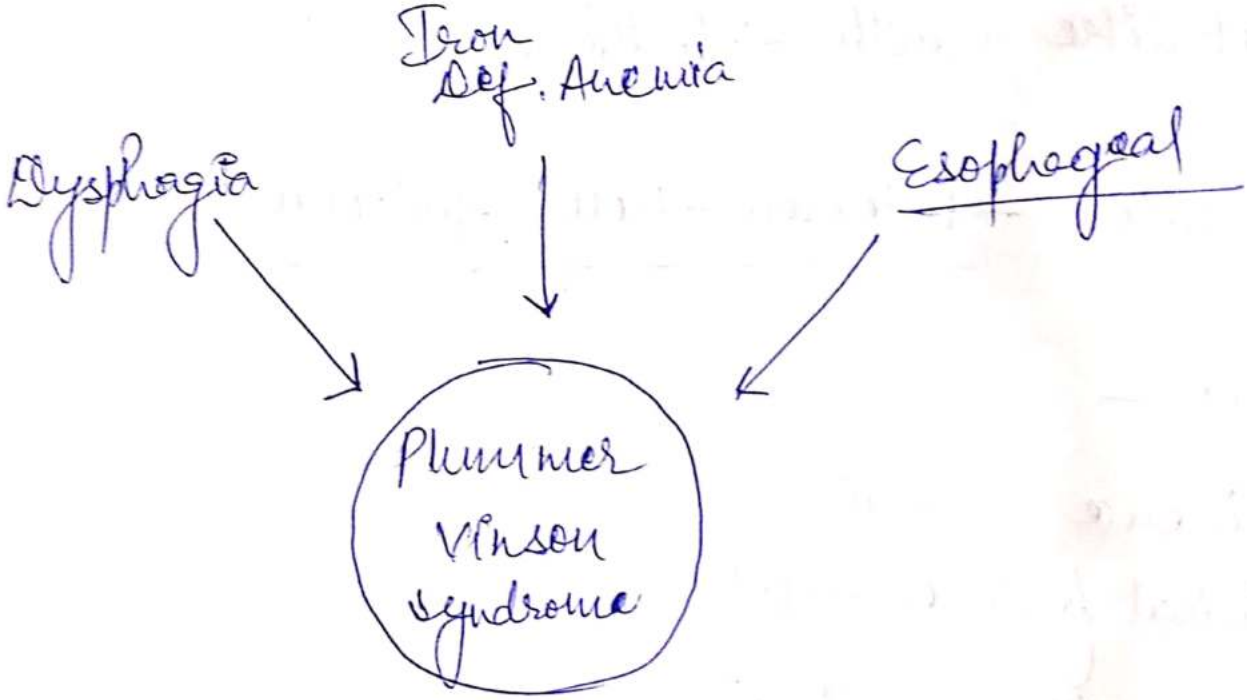


- Dysphagia — (1)
- Glossitis — (2)
- Koilonychias — (3).

Stomach and Duodenum

# Intussusception (आन्त्रान्तर प्रवेश)

Def. — It is a condition in which Part of Intestine telescopes itself.

— Disease of Stomach and Duodenum

— Medical Emergency — ①
— Involving obstruction — ②.

Factors —

— Types — ①
— causes — ②
— clinical features — ③
— Investigations — ④
— Treatment — ⑤

Types — Secondary Intussusception. — ①
— Primary Intussusception. — ②

- Secondary Intussception
  - Definite cause — (1)
  - Polyp — (2)
  - Lipoma — (3)
  - Lymphoma — (4)

- Primary Intussception
  - No definite cause — (1)
  - occurs b/w 6-9 Months — (2)
  - Ileo-colic — (3).

- Causes. -
  - Inflammation — (1)
  - Payer's patches — (2)
  - Respiratory tract viral — (3)
    function

- Clinical features -
  - Abdominal Pain — (1)
  - Vomiting — (2)
  - Oedema — (3)
  - Baccha Rota Hai Aur Sota Hai

## Investigations —

- Barium enema — (1)
- USG — (2)

## Treatment —

- General — (1)
- Conservative — (2)
- Surgery — (3)

(1) General —
- fluid and electrolyte Balance — (1)
- Nasogastric — (2)
- Antibiotics — (3)

(2) Conservative —
- Prophylactic Antibiotics — (1)
- Hydrostatic Reduction — (2)

Surgery —
- Paramedian incision — (1)
- oedema Reduced — (2)
- Intussusception — (3)
- copels Method — (4)
- Resection — (5)

# MECKEL's Diverticulum.

(आंत्र पुच्छ शो

- directly co-relates with the Bulge in lower p
of the Small Intestine.

- Most common congenital defect of GIT.

- MD - the passage of a large Amount of dark Red blood from the Rectum.

• Factors -

- complications — (1)
- clinical features — (2)
- Treatment — (3)

(1) complications — Intestinal Obstruction
Meckel's diverticulitis

Clinical features -

- M : F = 1 : 2 —— (1)
- Bleeding Per Rectum —— (2)
- Hernia —— (3)

Treatment -

- Surgical excision —— (1)
- Excision to end to end Anastomosis —— (1)

diagram -

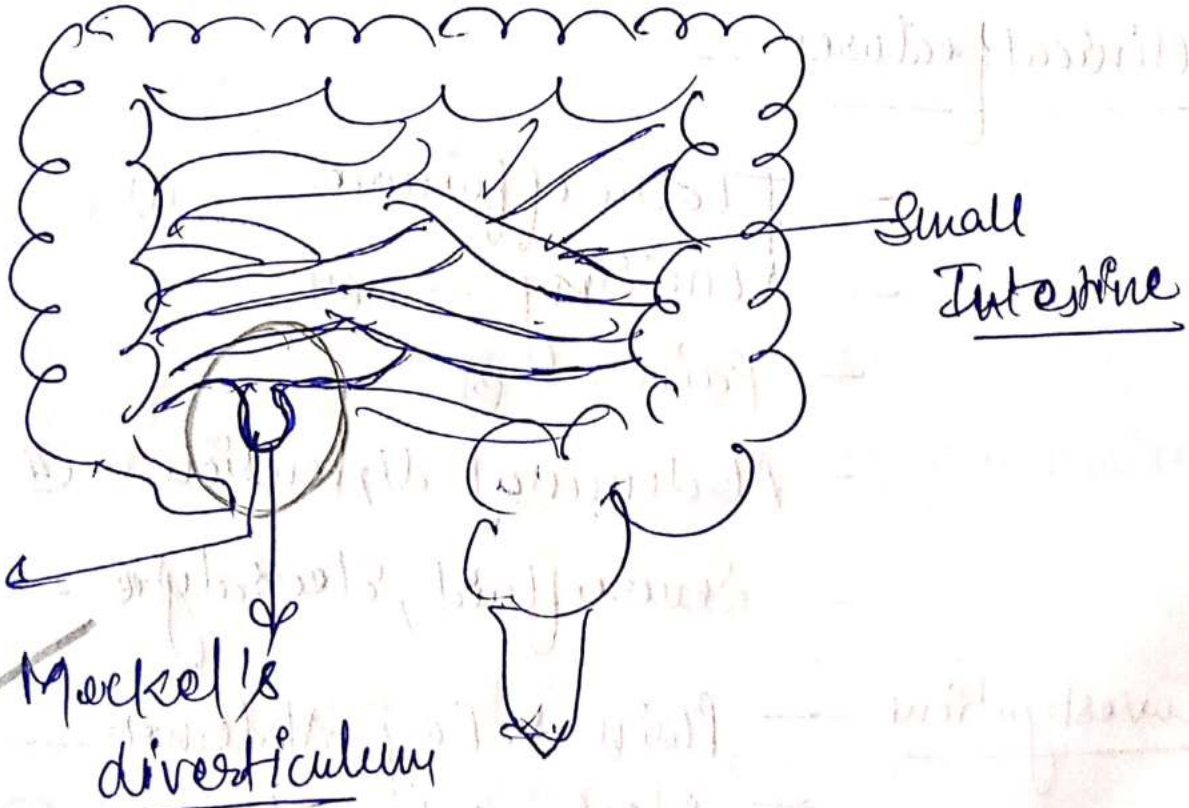

• Paralytic Ileus • (Neurogenic Ileus)

— Failure of Neuro Muscular Mechanism.
— directly co-relates — (Neurogenic ileus)

• Causes — Post-operation — ①
— Peritonitis — ②
— Hypokalaemia — ③
— Spinal Injury — ④

• Clinical features —
— Flatus offailure — ①
— Vomiting — ②
— Pain — ③
— Abdominal distension — ④
— Severe fluid, electrolyte — ⑤

• Investigations — Plain X-Ray Abdomen — ①
— Electrolyte study — ②

• Treatment — Primary cause — ①
— Ryle's tube Aspiration — ②
— control dehydration — ③

# Volvulus.

An obstruction due to knotting of the GIT.
Twisting or knotting can block the intestine and obstruct blood flow.

Factors –

- common site — (1)
- causes — (2)
- symptoms — (3)
- Investigations — (4)
- Treatment — (5)

common site – sigmoid colon — 60% (Anticlock) — (1)
– caecum — 30% (clockwise) — (2)

causes. – Chronic constipation — (1)
– Redundant sigmoid loop — (2)

- Symptoms — Abdomen pain Acute — (1)
  - Abdominal distension — (2)
  - Absolute constipation — (3)
  - Nausea — (4)
  - Vomitting — (5)

- Investigation — Abdominal Plain X-Ray — (1)
  - coffee Bean sign — (2)
  - Barium enema — (3)

- Treatment — uncomplicated — (1)
  - complicated — (2)

- uncomplicated — Sigmoidoscope — (1)
- complicated — Sigmoidopexy — (2)

## Caecum Volvulus :

- **Causes** — Mobile caecum. — (1)
  - Mal rotation — (2)

- **Features** — Mild Abdominal Pain — (1)
  - Nausea — (2)
  - Vomiting — (3)
  - Percussion — (4)
  - Rigidity — (5)
  - Abdominal distension — (6)
  - Abdominal constipation — (7)

- **Treatment** — Caecopexy — (1)
  - Hemicolectomy — (2).

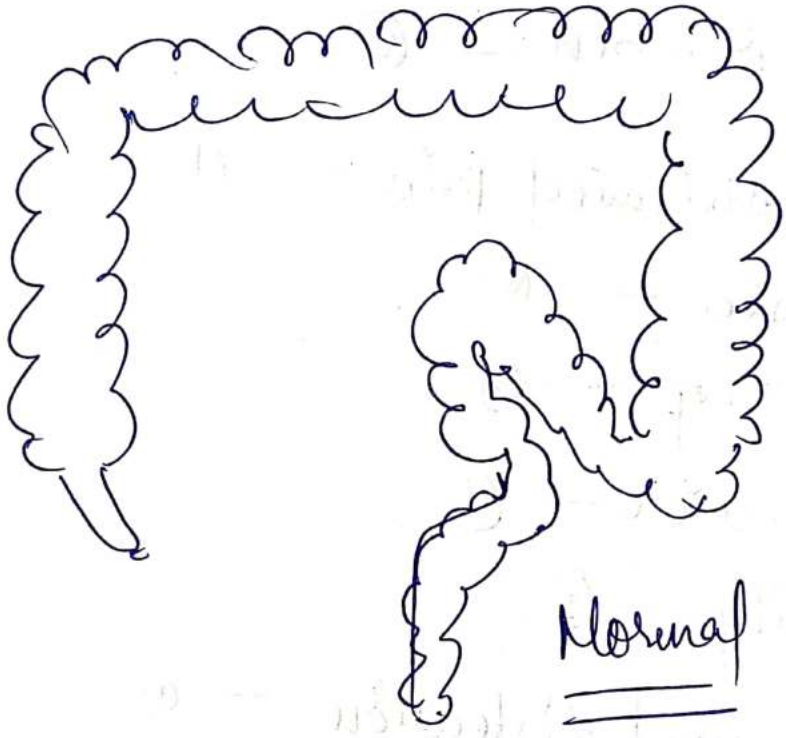

Normal

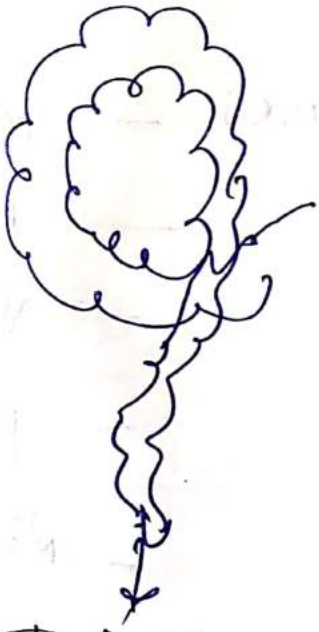

Twisting / knotting

Volvulus

# Appendicectomy

- Surgical operation to Remove the Appendix

- Factors —
  - Acute Appendicitis — (1)
  - Recurrent Appendicitis — (2)

Incisions —
- McBurney's grid Incision — (1)
- Lanz Incision — (2)
- Midline Incision — (3)
- Rutherford Incision — (4)

yers —
- skin — (1)
- Two Layers — (2)
- external oblique — (3)
- trans Abdominal Muscles — (4)
- Peritoneum — (5)

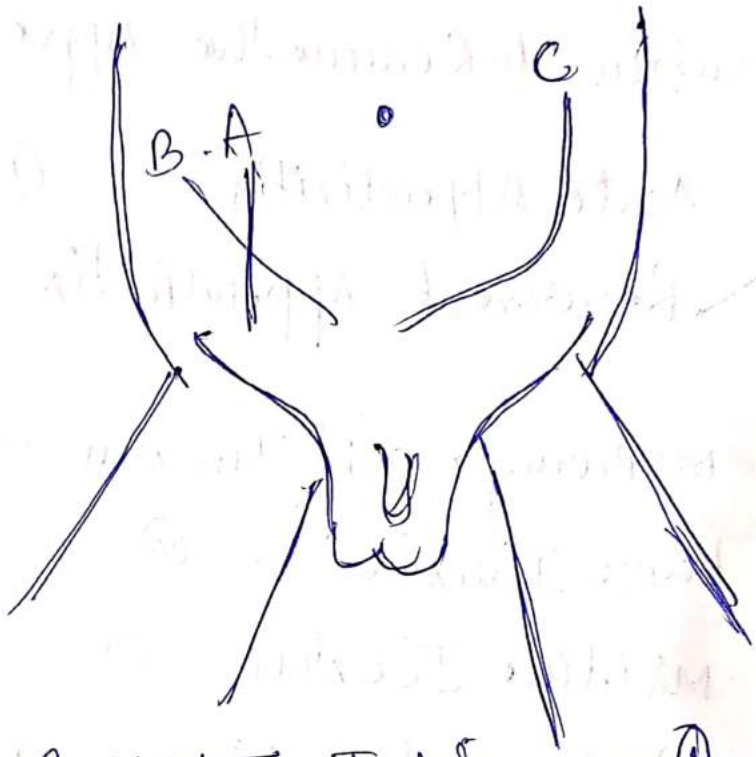


A – Grid Iron Incision — (1)

B – Lanz Incision — (2)

C – Rutherford Incision — (3).

- Post-operative –

  - Ryle's tube Aspiration — (1)
  - IV fluids — (2)
  - Antibiotics — (3)
  - oral fluids — (4)
  - suture Removed — (5)

# Congenital Hypertrophied Pyloric Stenosis

Blockage of the passage out of stomach

Junction B/w stomach and Intestine

Pylorus :- Gate —— (1)

Stenosis :- Abnormal Narrowing of Passage —— (2)

Factors :-

- Aetiology —— (1)
- clinical features —— (2)

Signs — Inspection —— (3)

- Investigations —— (4)
- Treatment —— (5)

Aetiology - Muscular Hypertrophy —— (1)

- Ganglion cell —— (2)

- Clinical features –
  - Vomiting — (1)
  - weight loss — (2)
  - Infant - Rapidly — (3)
  - constipation — (4)
  - oliguria — (5)

Signs – Inspection — (1)
- palpation — (2)
- Electrolyte imbalance — (3)

- Inspection – visible gastric peristalsis —
- palpation — Thickened pylorus — (2)

- Electrolyte imbalance – Alkalosis — (1)
  - Chloride — (2)
  - Potassium Ions — (3)

- Investigations – Barium X-Ray — (1)
  - USG — (2)

## Treatment –

**Medical** — Electrolyte imbalance — ①
— Atropine Methyl Nitrate — ②
— small frequent feeds — ③

**Surgical** – Incision — ①
— excision — ②

**Incision** — 3–4cm long in upper right Quadrant of Abdomen.

**Post-operative** –

— Feeding commence — ①
— Gradually Increased — ②
— Mucosa is repaired — ③

# Helicobacter Pylori Infection

- It is gram Negative Bacteria — ①
- 4-6 flagellated organisms — ②
- Factors :-
  - Points — ①
  - Pathogenesis — ②
  - Investigation — ③
  - clinical features — ④
  - Treatment — ⑤

- Points - Duodenal ulcer - 95%. — ①
  - Gastric ulcer - 75% — ②
  - Gastritis : 70% — ③
  - Gastric CA - 1-2% — ④

## Special Points –

- Helicobacter is Normally not found in saliva — (1)
- transmitted — faeco-oral / oral-oral } Route — (2)
- common in socio-economic group — (3)
- Location – Gastric epithelium. — (4)
- 95% in western country — (5)

## Pathogenesis –

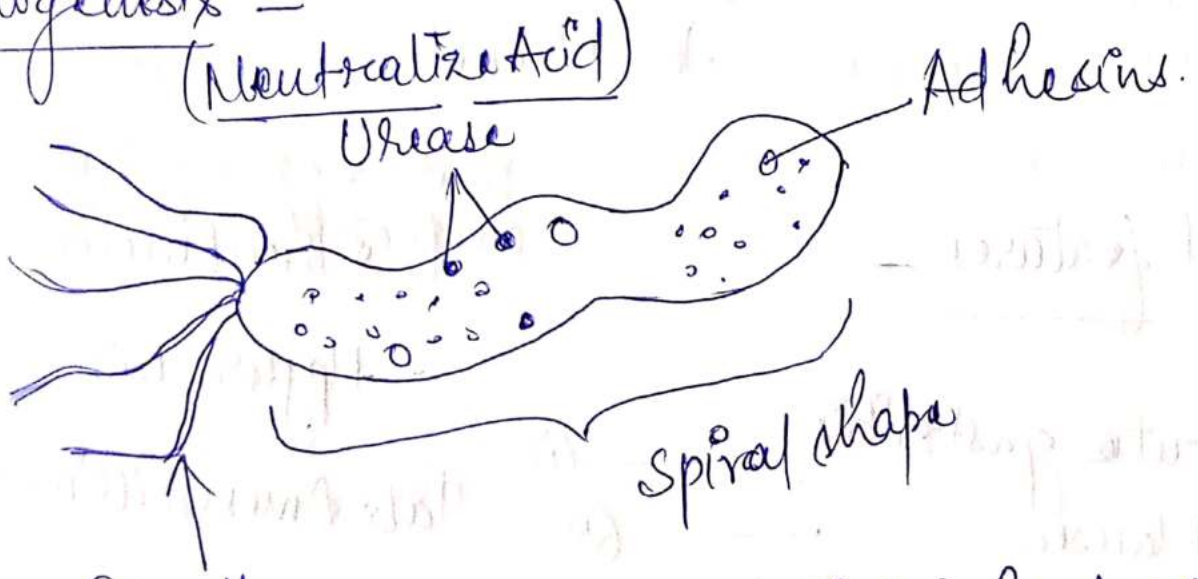


- H-Pylori Producer — (1)
- Negative feedback Mechanism — (2)
- Secretion of gastrin — (3)
- Infection in stomach — (4)
- Inflammatory response — (5)
- Hypersecretion of gastric Acid — (6)
- Duodenal Mucosa. — (7)
- Duodenal ulcer — (8).

- Investigation

- Urea breath test — ①
- Mucosal Biopsy — ②

- Urea breath test — C13 or C14 are ingested
  - C13 or C14 split off due urease — ②

- Mucosal Biopsy — Endoscopic biopsy — ①
  - PH Increased due to Phenol — ②

| | | | |
|---|---|---|---|
| Amoxy | A | HPKIT B Tinida | Omeprazole |
| | A | B | C |

Pantaprazole — 40mg
Omeprazole — 20mg

- Clinical features —

- Acute gastritis — ①
- Nausea — ②
- Chronic gastritis — ③
- Pain in stomach — ④
- Bloating — ⑤
- Vomiting — ⑥

Treatment

- Hylori kit —

Tab - Amoxycillin —

Tab - Clarithromycin 500mg

Tab - Tetracycline

Tab - Metronidazole

Tab - Tinidazole —

# Peptic ulcer - (PUD) Diseases

Peptic ulcer directly co-relates with the lesion lining of digestive tract.

Location - stomach —— (1)
duodenum —— (2)

Caused by - Pepsin —— (1) (Acid pepetic diseases)
- stomach Acid —— (2).

factors :-

- causes —— (1)
- site —— (2)
- classification —— (3).
- complications —— (4)
- चिकित्सा —— (5)

- Causes. :
  - Acid in High concentration — (1)
  - Mucosa Mechanism — (2)

- Site -
  - Oesophagus — (1)
  - stomach — (2)
  - Duodenum — (3)
  - Jejunum — (4)
  - Meckels diverticulum — (5)
  - Gastro-enterostomy — (6).
  - Anastomotic ulcer — (7)

Duodenal ulcer : Gastric ulcer
30 : 01

- Classification -
  - Duration (A/c to Duration)
    - Acute Peptic ulcer — (1)
    - chronic Peptic ulcer — (2).
  - A/c to site
    - chronic Duodenal ulcer — (1)
    - chronic gastric ulcer — (2)
    - Anastomotic ulcer — (3)
    - combined — (4).

# Gastric ulcer (आमाशयगत व्रण)

Also called - Peptic Ulcer.

Stomach Acids damages the lining of digestive tract

Factors —

- Causes —— ①
- Pathology —— ②
- Classifications —— ③
- Clinical features —— ④
- Investigations —— ⑤
- Management —— ⑥

Causes. - Defective gastric Mucosal Barrier —— ①

- Helicobacter pylori Infection —— ②
- Duodenal-gastric reflux —— ③
- Ischemia of gastric mucosa —— ④

- Pathology -

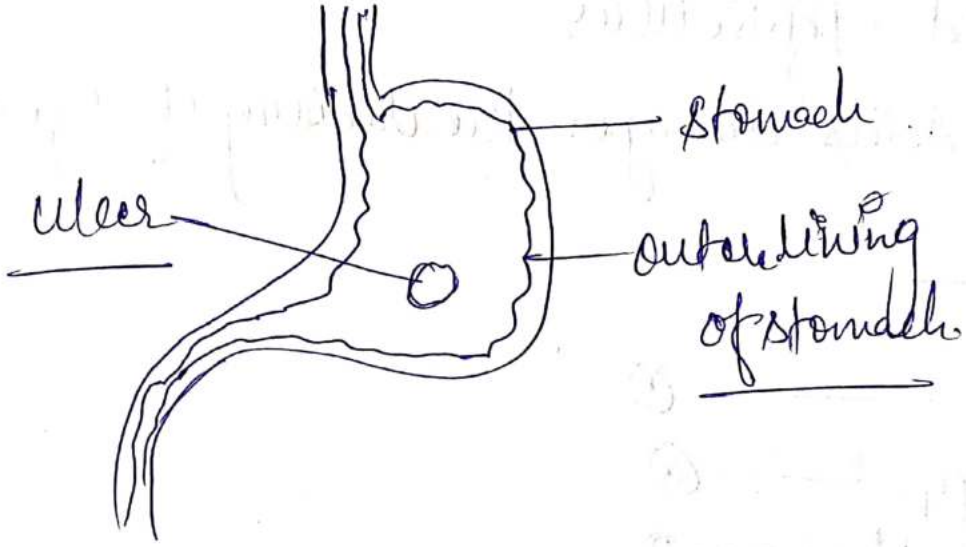


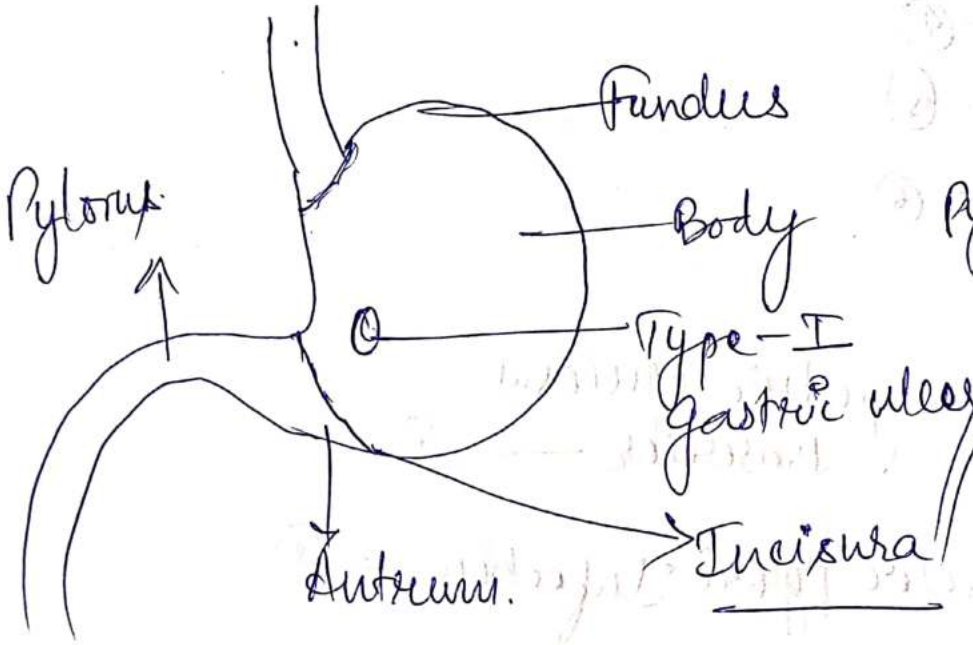


55%

(A) Type I gastric ulcer




25%

(B) Type II gastric ulcer

• Classification

| | Level | % | |
|---|---|---|---|
| – Type I → | (N) → | 55% | — (1) |
| – Type II → | High → | 25% | — (2) |
| – Type III → | High → | 15% | — (3) |
| – Type IV → | (N) → | 05% | — (4) |

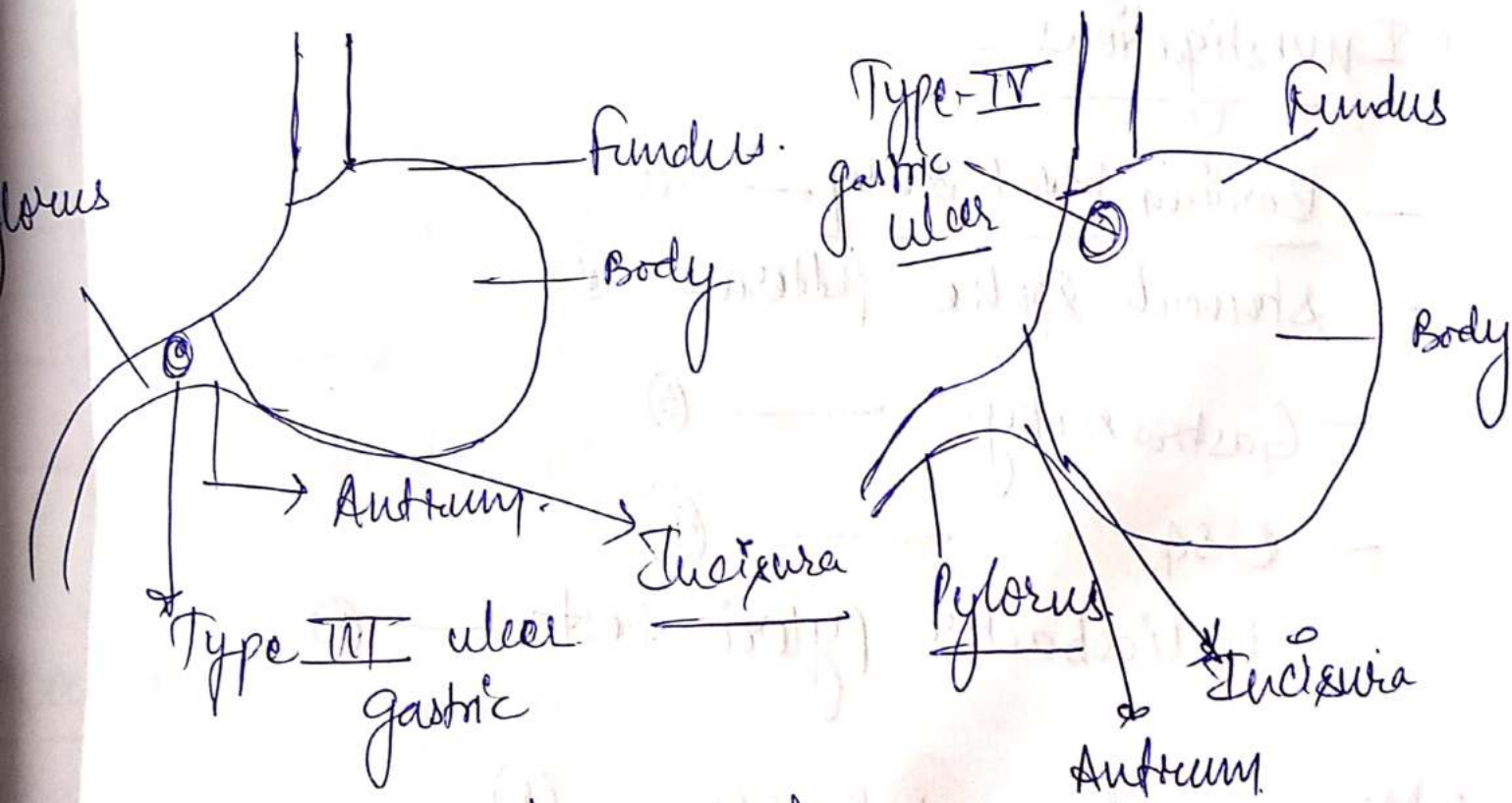


(C) – 15% Level. High

(d) 5% Level. Normal

- Clinical features –

  - Pain — (1)
  - Vomiting — (2)
  - Appetite — (3)
  - weight — (4)
  - On Examination — (5)

- Investigations –

  - Barium Meal study — (1)
  - Stomach Spoke Pattern — (2)
  - Gastroscopy — (3)
  - USG — (4)
  - Helicobacter Pylori test — (5)

- Management – Antacids — (1)

  - $H_2$ Receptor Blocker — (2)
  - Proton Pump Inhibitor — (3)
  - Amoxycillin – 500mg — (4)
  - Pantop tab – 200mg — (5)

# Chronic DuoDenal ulcer (परिणाम शूल)

Also called as — Peptic ulcer

A sore type — Lining of oesophagus — (1)
stomach — (2)
small Intestine — (3)

Factors —

- Causes — (1)
- Pathology — (2)
- clinical features — (3)
- Investigations — (4)
- Management — (5)

Causes. — Hyper Acidity — (1)
— Bacterial cause — (2)
— Emotional cause — (3)
— Food Habits — (4)
— Endocrine cause — (5)
— Genetic — (6)
— NSAID steroids — (7).

- Pathology —

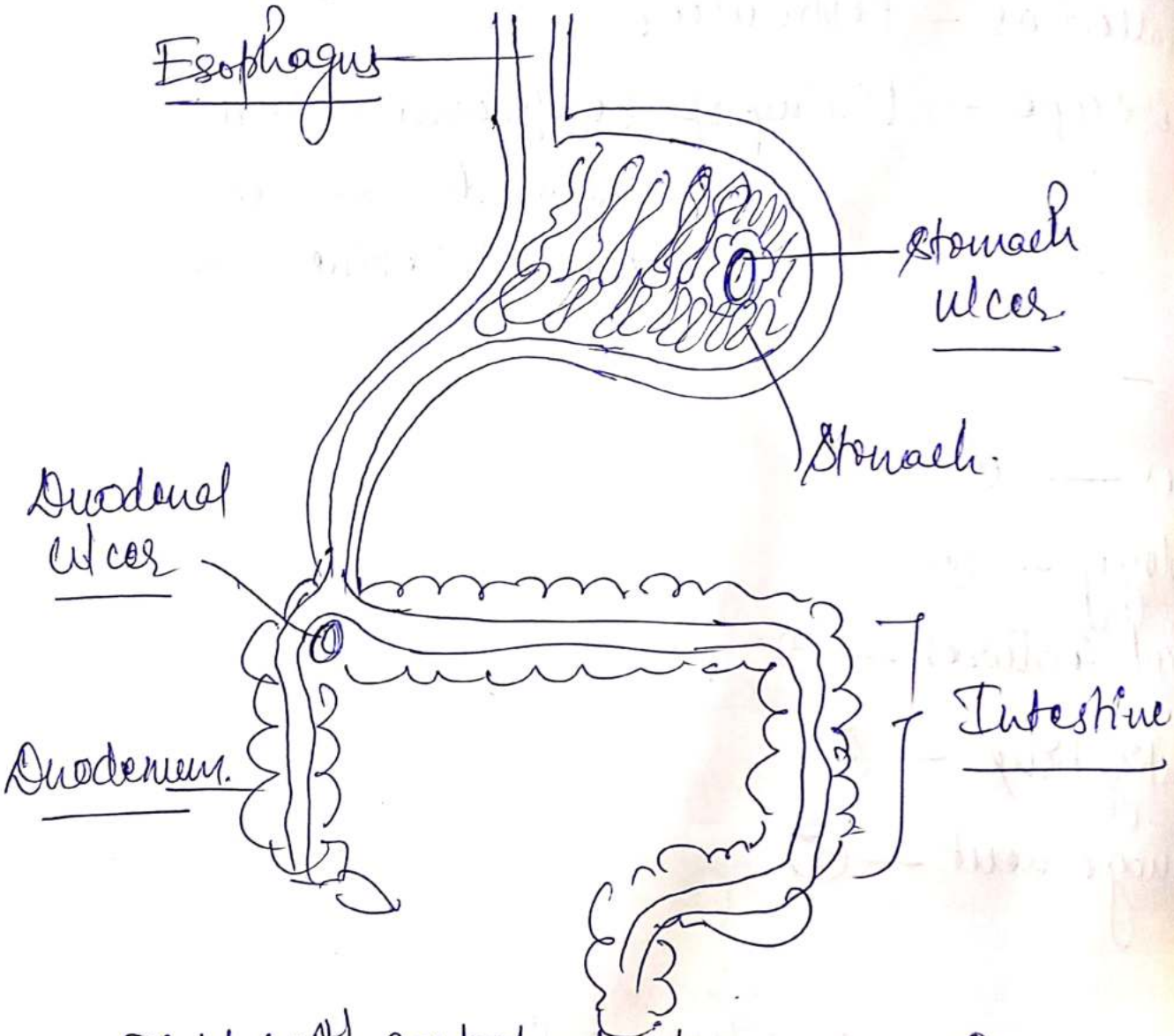


— First (1st) part of duodenum — ①
— perforate and Bleed — ②
— Giant ulcer — ③
— Kissing ulcer — ④ (two opposing ulcers)

146

## Clinical features -

- Pain — (1)
- Vomiting — (2)
- Appetite — (3)
- weight — (4)
- Melaena — (5)
- Tenderness. — (6).

## Investigations -

- Barium X-Meal X-Ray — (1)
- Gastroscopy — (2).

## Management -

- Tab Amoxycillin — (1)
- Tab Pantop — (2)
- Tab - Metrogyl — (3)
- Tab Omeprazol — (4)
- Antacids — (5).

## आयुर्वेद चिकित्सा

- रसायन — (1)
- सुकुमार घृत — (2)
- लघु सूत शेखर वटि — (3)
- आमलकी चूर्ण — (4)
- अविर्वेतिक चूर्ण — (5)
- हरितकी चूर्ण — (6).

# Hour Glass Stomach / contracture

- Abnormal constriction of stomach.
- Dividing two cavities
- Cavities -
  - Cardiac
  - Pyloric

Ref - शल्य तंत्र / Surgery

- More common in females.

- **Factors** -

- Causes — ①
- clinical features — ②
- Investigations — ③
- Treatment — ④.

- **causes** - Contraction of ulcer — ①
  - Scarformation — ②
  - Both surfaces — ③

## Clinical features —

- Fullness — (1)
- distension — (2)
- Vomiting — (3)
- weight loss — (4)
- Appetite loss — (5)



## Investigations —

- Barium Meal X-Ray — (1)
- Gastroscopy — (2)

## Treatment —

- Gastrectomy — (1)
- Billorth — I. — (2)
- gastero - duodenal Anastomosis — (3)

# TEA Pot Deformity

- A long standing less curvature gastric ulcer causes shorter of lesser curvature due to fibrosis.
- Such stomach Resembles a teapot.
- Treatment - Partial gastrectomy with Billroth Anastomosis

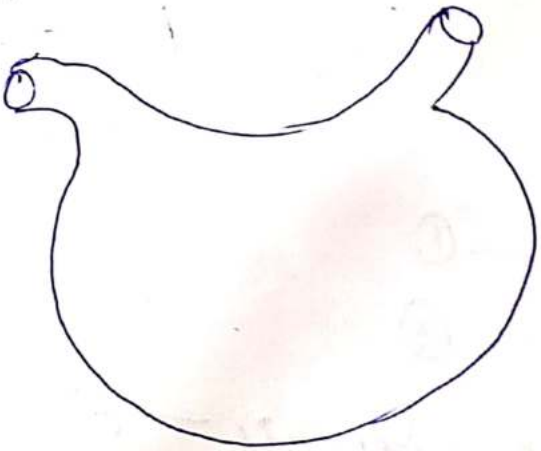

Hand bag stomach

Teapot stomach

# CA of Stomach (आमाशय अर्बुद)

- Also called – gastric cancer.
- 'captain of Men of death'

- More common in Males
- Mostly found in Blood group A.

Factors –

- Aetiology ——— (1)
- Classifications ——— (2)
- TNM Classifications ——— (3)
- Clinical features ——— (4)
- Investigations ——— (5)
- Treatment. ——— (6)

Aetiology – Age/sex – 59 years (50–70 yrs)

Male = 01

Female = 02

- Diet ——— (1)
- Gastritis ——— (2)

b). Hypogamma-globulinaemia — (4)
- H-Pylori Infection — (5)
- Gastric Resection — (6)
- Pernicious Anaemia — (7)
- Chronic gastric ulcer — (8)
- Benign Polyp — (9)
- Genetic factor — (10).

- Diagram. -

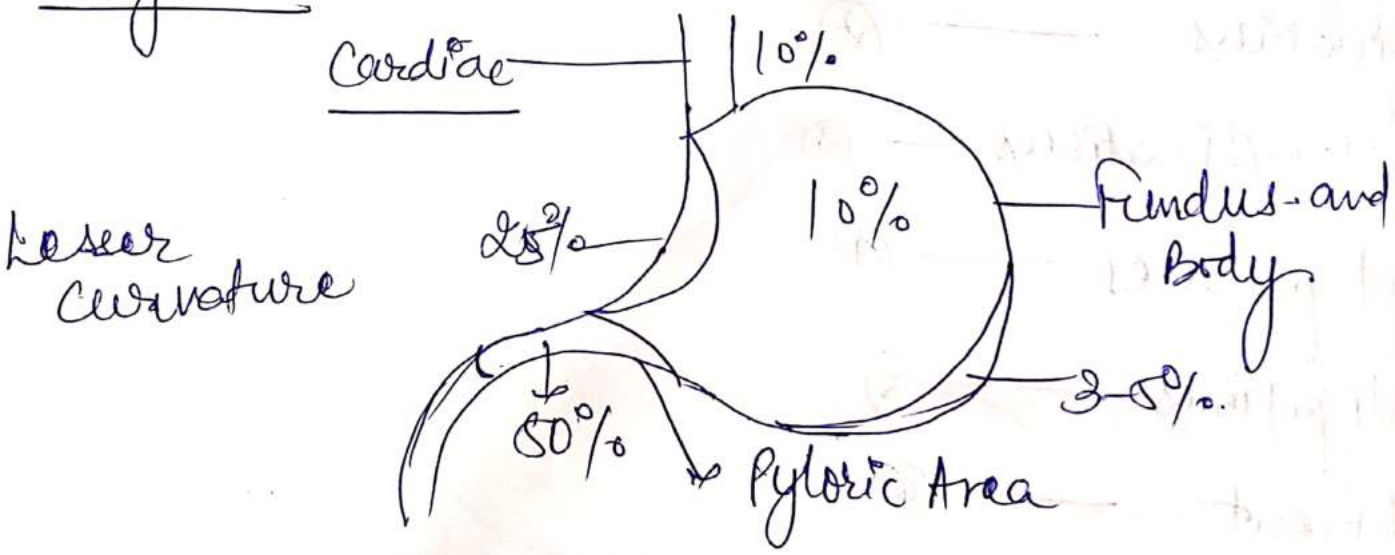


- Cardias — 10% — (1)
- Fundus and Body — 10% — (2)
- Lessor curvature — 25%
- Pyloric Area — 50%

Greater Curvature -

- Cardia → 10% — ①
- Antrum → 50% — ②
- Fundus → 12% — ③
- Multiple → 3% — ④
- Body → 18% — ⑤
- Diffuse → 07% — ⑥.

<u>classification</u> —

- <u>Gross/ Macroscopic</u> — ① —
- Japanese classification — ②
- Advanced gastric cancer — ③

> depend depth of <u>Invasion</u>

- Spread
  - Direct — ④
  - Lymphatic spread — ⑤
  - Blood spread — ⑥
  - Transperitoneal spread — ⑦

① Gross/ Macroscopic –

- cauliflower or Proliferative —— ①
- Cauliflower soft tumors —— ②
- Broad Pedicles —— ③
- Malignant —— ④
- commonest type —— ⑤
- circular in shape —— ⑥

② Depending on depth of Invasion :

- Protruded
- superfical
- excavated

- Polypoid



- flat



- excavated

Spread —
- Direct — (1)
- Lymphatic spread — (2)
- Blood spread — (3)
- Transperitoneal spread — (4).

TNM classification —

Tumor —
- $T_0$ — No evidence — (1)
- $T_1$ — Sub Mucosa — (2)
- $T_2$ — Muscularis — (3)
- $T_3$ — Serosa layer — (4)
- $T_4$ — Invasion of serosa — (5).

Nodes —
- $N_0$ — No evidence — (1)
- $N_1$ — 1-2 Lymph Nodes — (2)
- $N_2$ — 3-6 Lymph Nodes — (3)
- $N_3$ — 7 or more Nodes (+ve) — (4).

Tumor — Metastasis —
- M0 — No Metas
- M1 — Metastas Present

- Clinical features —
  - Loss of Appetite — (1)
  - Loss of weight — (2)
  - Vomiting — (3)
  - Obstruction — (4)
  - Abdominal Mass — (5)
  - Dysphagia — (6)
  - Anaemia — (7)
  - Lymph Node Enlargement — (8)
  - Liver Enlargement — (9)
  - Irish Node enlargement — (10)

- Investigations — GFT test — (1) Gastric test
  - Barium Meal X-Ray — (2)
  - Endoscopy — (3)
  - USG — (4)
  - Tetracycline flo

## Treatment –

- Surgical treatment — (1)
- Laprotomy — (2)
- Radical operations — (3)
- Chemotherapy — (4)
- Radiotherapy — (5)
- Gastrectomy — (6)

- Gastrectomy —
  - Total Radical gastrectomy — (1)
  - Upper Radical gastrectomy — (2)
  - Lower Radical partial gastrectomy — (3).

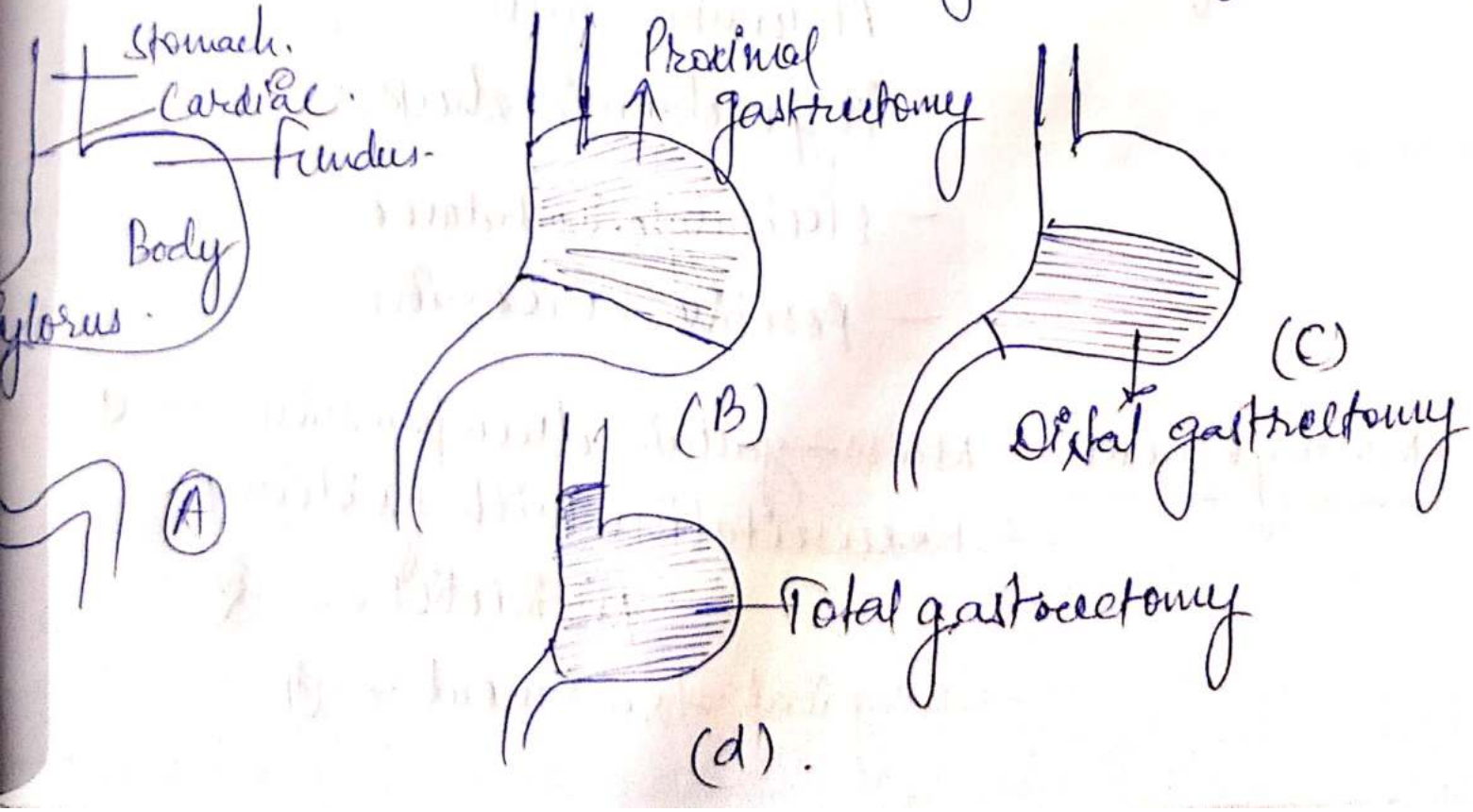

## आमाशय विस्फारण (Acute Dilatation of stomach).

- Def - Acute dilatation of stomach —— (1)
  Atonic gastric wall. —— (2).
  peristalsis

- Causes - Post-operative complications —— (1)
  - Mechanical obstruction —— (2)
  - Eating disorder —— (3)
  - Spinal cord Injury —— (4)
  - Aerophagia —— (5)

- clinical features - Hiccough / Hiccups
  - Abdominal Pain
  - Hypovolaemic shock
  - Electrolyte Imbalance
  - Positive succession

- Management - Naso-gastric decompression
  - Resuscitation with fluids and Antibiotics —— (2)
  - Surgical treatment —— (3)

# Diseases of Large Intestine

## Crohn's diseases

(स्थानीय आन्त्र शोथ)

It is a chronic Inflammatory Bowel disease.
- Affects lining of digestive tract.
- Also called – ileitis / enteritis
- Inventor – Burrill Bernard crohn (Gastero enterologist)

Ref – शल्य तंत्र / Surgery

Factors –
- Aetiology — (1)
- Pathology — (2)
- clinical features — (3)
- stages. — (4)
- Investigations — (5)
- Treatment. — (6)

① Aetiology -

- Chromosomal genetics — ①
- Auto-Immune — ②
- Infections — ③
- Tabacco — ④
- Smoking — ⑤
- Ischaemia — ⑥
- Stress — ⑦
- toxic substance Absorption — ⑧

② Pathology -

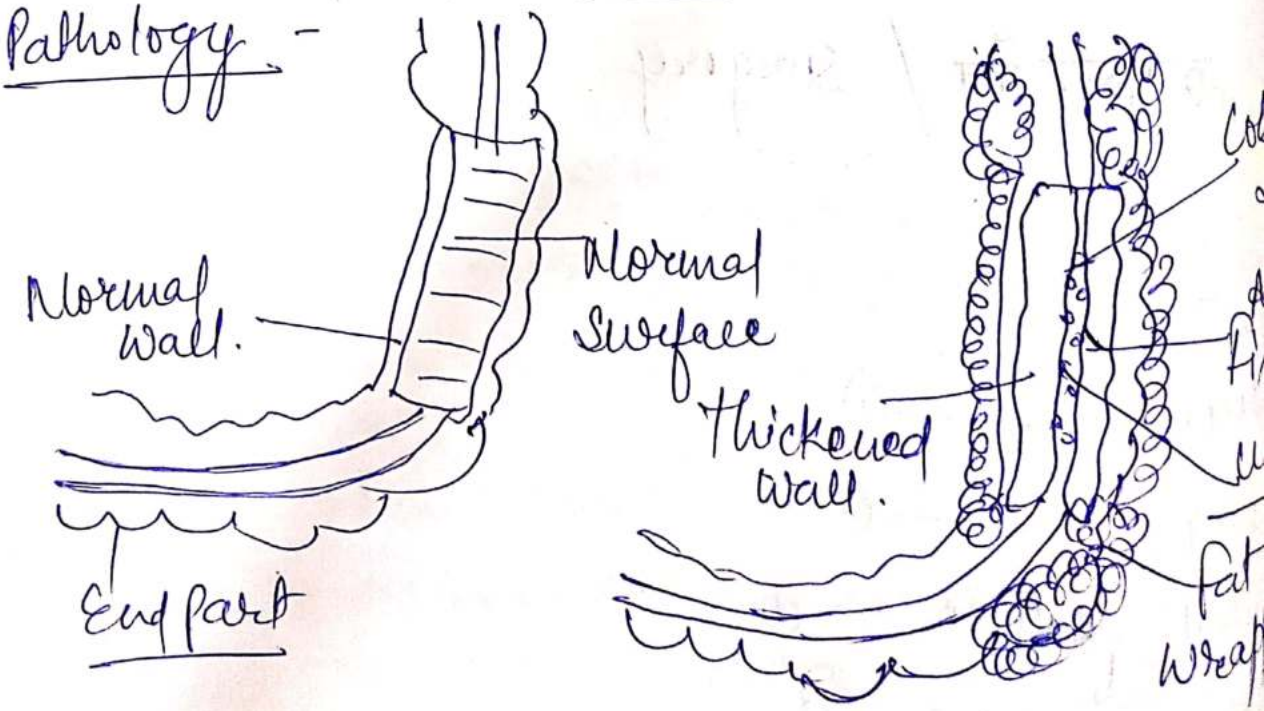

① Normal Intestine Pathology

- Normal wall. — ①
- Normal Intestine surface — ②
- No swelling — ③
- Clear track. — ④
- No Dilated Part. — ⑤

② Crohn's disease Pathology

- Ulceration — ①
- Nodes Enlarged — ②
- Cobblestone surface — ③
- Thickened wall — ④
- Fat wrapping — ⑤
- Anal fissure — ⑥

Clinical features
- 20-30yrs Age — ①
- Slow progressive — ②
- Lower Pain — ③
- diarrhoea — ④
- weight loss — ⑤ - Fever — ⑥

- Stages. -

  - ileo-colitis — (1)
  - Acute Intestinal obstruction — (2)
  - Fistula formation. — (3)

- Investigations -

  - cobblestone Reticulation — (1)
  - colonoscopy — (2)
  - Fistulography — (3)

- Treatment
  - General — (1)
  - Conservative — (2)
  - Surgical — (3)

- General
  - Rest — (1)
  - Stop smoking — (2)
  - High Protein diet — (3)
  - Vitamins. — (4)
  - stop tobacco. — (5).

Medical - Monoclonal Antibody — ①
- Azathioprine — ②
- Infliximab — ③
- Corticosteroids — ④
- Metronidazole — ⑤

Surgery - Resection — ①
- Strictureoplasty — ②
- Colectomy — ③

आयुर्वेदिक चिकित्सा -

- मुस्त अरिष्ट — ①
- कोष्ठ संजीवनी वटी — ②
- तक्र पान — ③
- घृत — ④
- पंचगव्य घृत — ⑤
- शतपुष्प चूर्ण — ⑥

Diagram -

# Intestinal Tuberculosis

- Chronic disease
- Roughened type
- Rough appearance in Intestine.




- Types
  - Ulcerative type — (1) 60%.
  - Obstructive type — (2) 10%.
- Clinical features
  - Pain Abdomen
  - Diarrhoea
  - Bleeding
  - Anaemia.
  - Fever
- Investigations
  - X-Ray
  - Rectum examination
  - USG
  - ERS
  - TURS.
  - colonoscopy
  - stool examination
- Management
  - Anti TB drugs.
  - Antibiotics
  - Blood
  - Nutrition diet
  - Tab-spasdone

# Vermiform Appendix

- Vermiform Means – worm shaped.
- Postero-Medial Aspect of caecum (2cm)

↕

Insertion of ileum into caecum.

Ref – शल्यतंत्र / Surgery

Factors –

- Layers. —— ①
- Muscles —— ②
- Blood supply —— ③
- Positions —— ④
- Locations —— ⑤
- Anomalies —— ⑥

Layers –
- Serous —— ①
- Muscle coat —— ②
- Sub Mucosa —— ③
- Mucosa —— ④

— Muscles — Aliatus Muscularis — (1)
sub Mucosa — (2)
Blood supply — (3)
Appendicular artery

• Anatomical Position —

— Retrocaecal → 120'clock — 70% —

— Pelvic → 40'clock — 20% —

— Pre. ileal
Post ileal → 20'clock — 02% —

— Subcaecal → 6'clock — 02%.

— Paracaecal → — — 1%.

— Paracolic → Ascending colon — 1%.



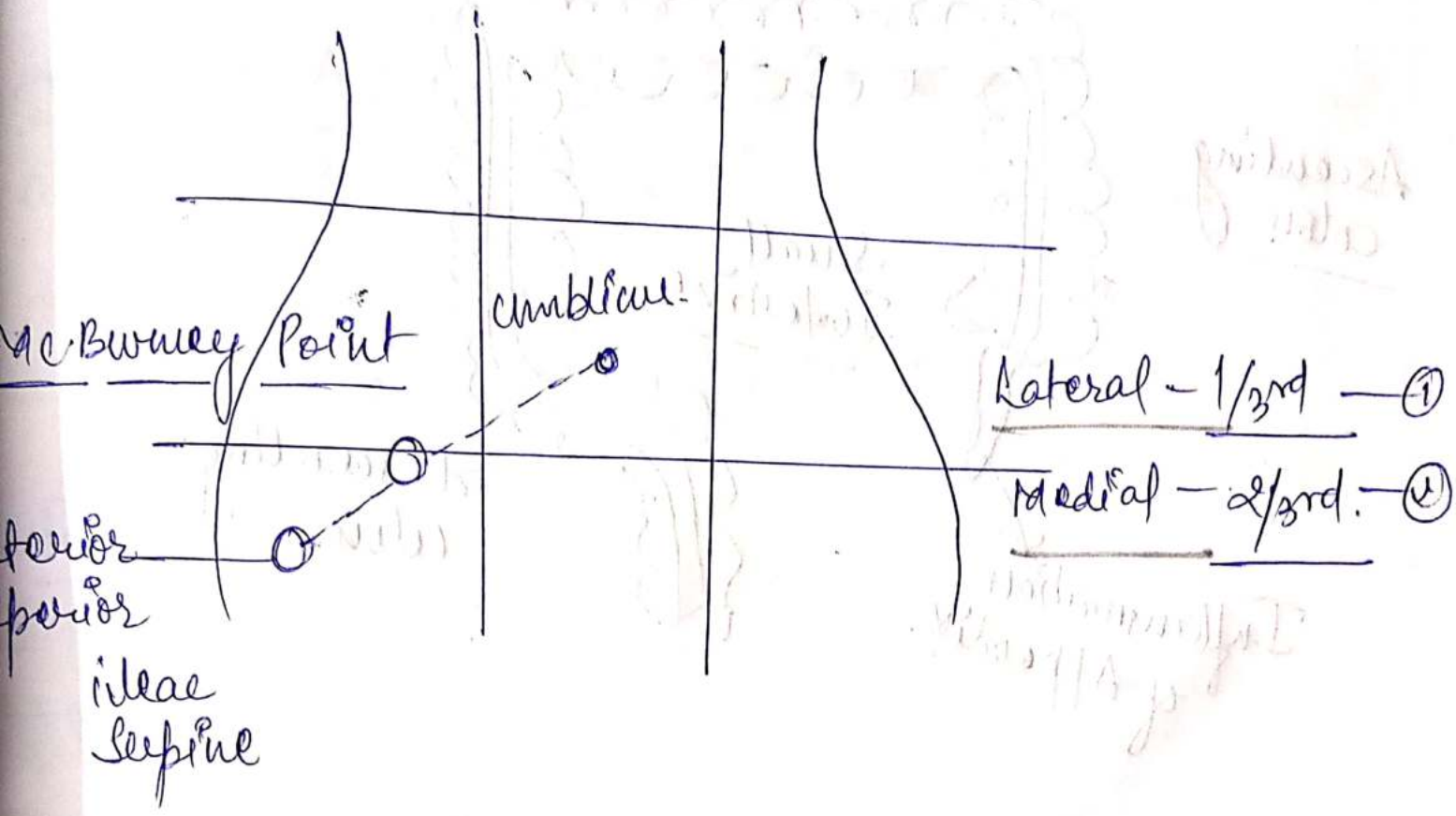


Location -

- Mc-Burney's Point - Lateral - 1/3rd - (1)
  - Medial - 2/3rd - (2)
  - taenia coli. - (3)

Functions - Defense Mechanism

Anomalies - Agenesis - (1)
- Duplication - (2)
- Inversion - (3).

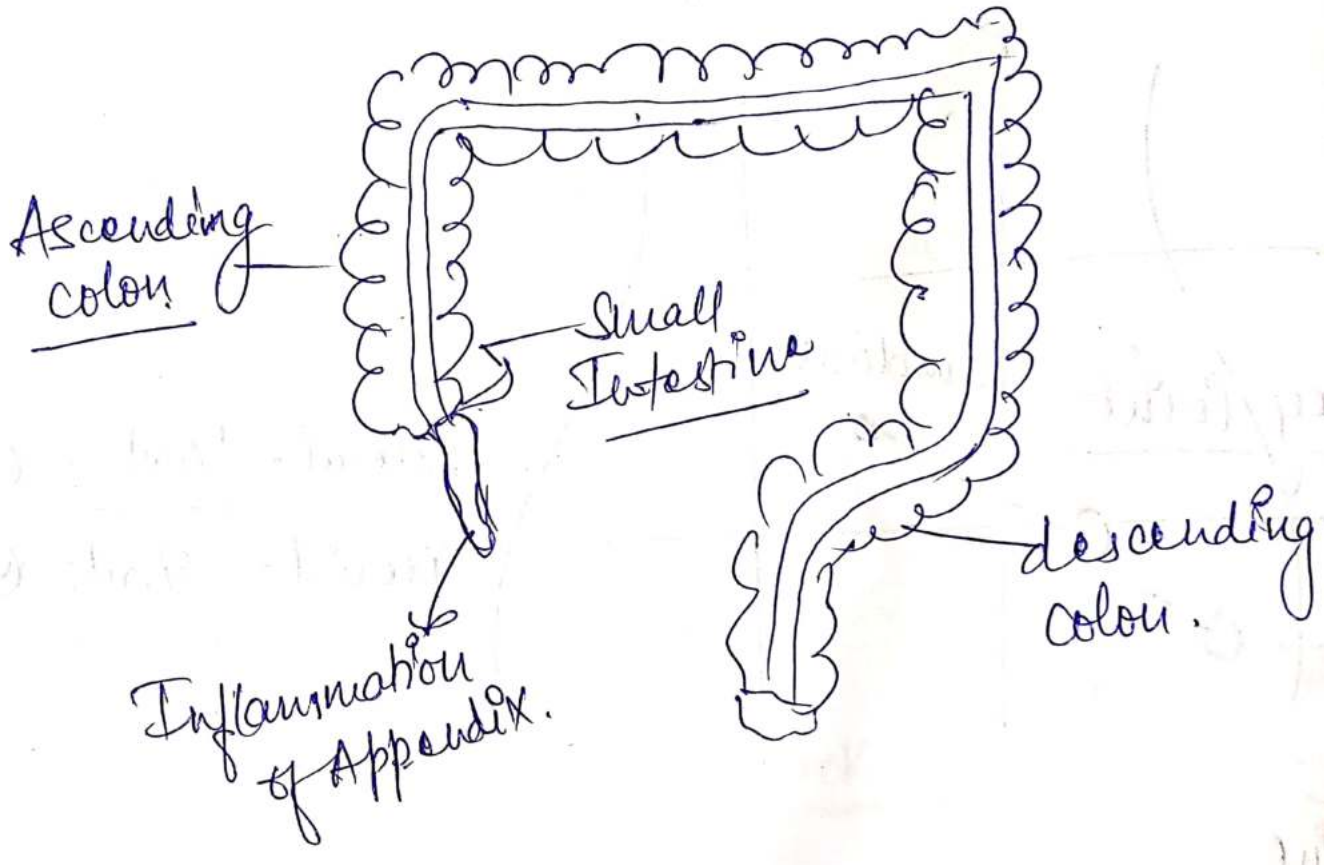

# Appendicitis (अपेंडिक्स शोथ)

In which Appendix becomes Inflammed and filled with Pus

- Pouch like structure
- Attached with Large Intestine

**Factors** -

- Causes —— (1)
- Types. —— (2)
- Pathology —— (3)
- Symptoms. —— (4)
- Signs —— (5)
- Investigation —— (6)
- Treatment —— (7)

**Causes** - Lumen obstruction —— (1)

- Bacteria —— (2)
- Inflammation —— (3)
- Pus —— (4)
- Pain —— (5).

- Types. — Acute Appendicitis — (1)
  - Sub Acute — (2)
  - Recurrent — (3) — Right Lower Quadrant Pain
  - Chronic — (4)

(1) Acute Appendicitis — Initial stage — (1)
- Initial signs. — (2)
- Initial Symptoms — (3)

(2) Sub Acute Appendicitis — Spontaneously occurs. — (1)

(3) Recurrent — Full Blown Appendicitis — (1)

(4) Chronic Appendicitis — Thickened — (1)
- Scaring — (2)
- Full pus. — (3)
- Inflammed — (4).

• Pathology -

- obstructive — ①
- Non- obstructive — ②

① obstructive — Mucosal Inflammation — ①
- Hyperplasia — ②
- Infection — ③
- Distension — ④
- Multiplication (Bac) — ⑤
- occulated capillaries — ⑥
- Rupture Hiatus — ⑦

Non- obstructive —
- Bacteria — ①
- Inflammation — ②
- Red Appendix — ③
- thrombosis — ④
- gangrene — ⑤

- Symptoms —

Murphy's syndrome (Traid)

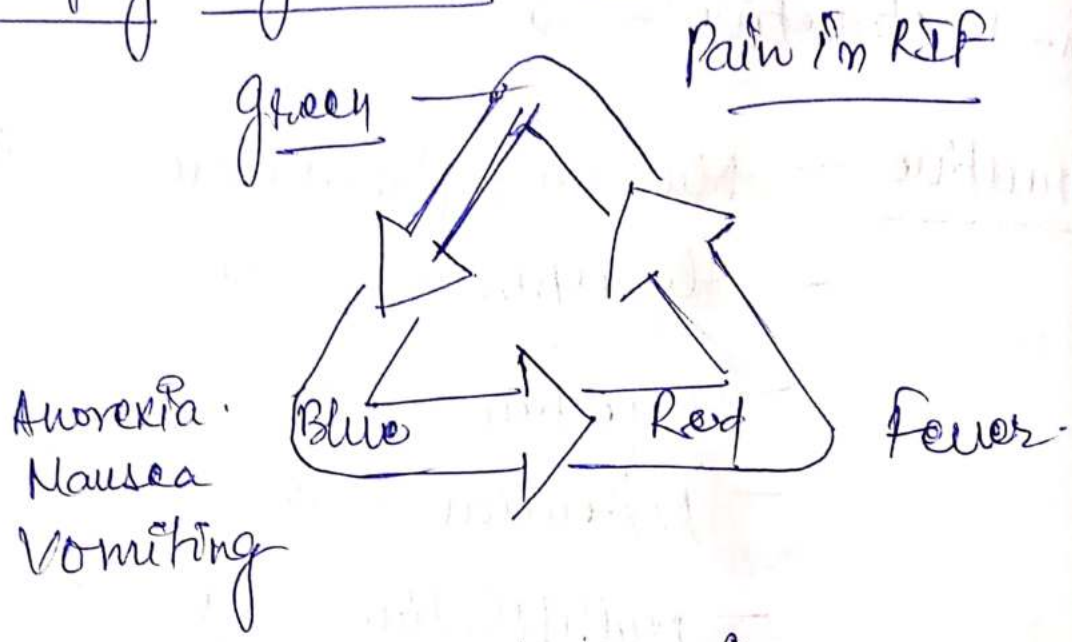


Pain — Severe colic type pain. — (1)
— Visceral Pain — (2)
— Somatic Pain. — (3)

- Vomiting — once or twice — (4)

Fever — Low fever — (5)

— Haematuria — (6)
— Constipation — (7)
— Anorexia — (8)
— Nausea — (9).

Signs –

- cough tenderness — (1)
- Blumberg's sign — (2)
- Shoozen triangle — (3)
- Rowsing sign — (4)
- Per. Rectum — (5)
- Baldwing test — (6).

Investigation –

- Leucocytosis — (1)
- Plane X – Ray — (2)
- USG. — (3)

Differential Diagnosis –

- Enterocolitis — (1)
- Meckel's diverticulum — (2)
- worm ball. — (3)
- Torsion — (4)
- typhilitis — (5)
- Acute Pancreatitis — (6)
- Ectopic gestation — (7).

• Treatment

- surgical treatment
- conservative treatment.

# Ulcerativecolitis (वृहदान्त्र शोथ)

UC is directly co-relates with the chronic Inflammatory Bowel disease

Occurs in Large Intestine (colon) and Rectum.

- Also called — UC, colitis ulcerosa

Factors -

- Aetiology — (1)
- Pathology — (2)
- Clinical features — (3)
- Types — (4)
- Investigations — (5)
- Managament — (6)

① Aetiology – Auto-immune factor — ①
– Dietary factors — ②
– Mucin production — ③
– Psychomatic factors — ④
– Genetic factors — ⑤

• Pathology – Pancolitis

– Lesion
– Abscess.
– colitis
– Proctitis
– Inflammation
– Pseudopolyposis
– spasm
– Pancolitis
– Backwash Ileitis

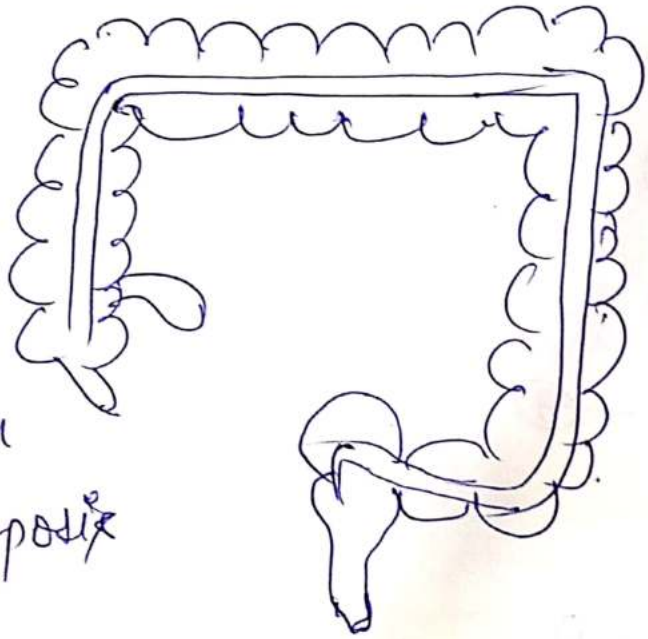

①

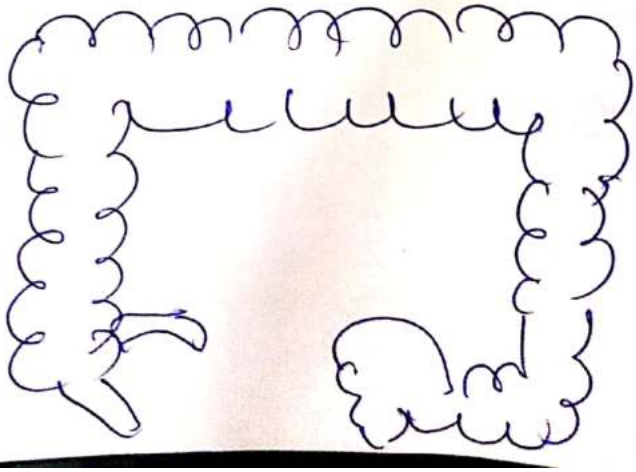

②. Backwash Ileitis

## Clinical features -

- M:F = 1:2 — (1)
- Age - 30-40 yrs — (2)
- watery diarrhoea — (3)
- severe dehydration — (4)
- Mal Nutrition — (5)
- Anaemia — (6)
- Acute Attack — (7)
- Relapse — (8).

## Types -

- Mild colitis — (1)
- Moderate colitis — (2)
- Severe colitis — (3)

- Mild - 4 stools/day — (1)
- Moderate - 6 stools/day — (2)
- Severe - 6 stools/day — (3).

- Investigation -

— Barium Enema — (1)
— Colonoscopy — (2)
— Plain-x-Ray Abdomen — (3)

- Management

— General — (1)
— Conservative — (2)
— Surgical — (3).

(1) Conservative — Hospitalization — (1)
— Sedatives — (2)
— tranquilizers — (3)
— Anti-diarrhoeal drugs — (4)
— Antibiotics — (5)
— Corticosteroids — (6)
— cyclosporines — (7).

- Surgery — Proctoscopy
— Rectotomy → haprocotomy

# Rectum carcinoma (गुदा अर्बुद)

Rectum carcinoma is directly co-relates with the colon cancer.

- A cancer of colon or Rectum.
- Located in digestive tract Lower end.

Diseases of Rectum and Anal canal.

**Factors** -

- Diet — (1)
- Smoking — (2)
- Alcohol — (3)
- Family history — (4)
- Endometrium cancer — (5)
- Stomach cancer — (6)
- Biliary tree — (7)
- ovary — (8)

**Types** -

- Annular — (1) A
- Polypoidal — (2) P.
- Ulcerative — (3) U
- Diffuse — (4) D.
- colloid — (5) C.

① Annular — common rectosigmoid junction —
— constipation present — ②
— Intestinal obstruction present —
— 12–18 Month growth — ④
— Napkin Ring deformity — ⑤

② Polypoidal — Ampulla of Rectum — ①

③ Ulcerative — Raised edges — ①
— growth — ②
— transverse direction — ③

④ diffuse — often seen in PT — ①

⑤ colloid — Mucus Production Increases — ①
— common in youngsters — ②

## Clinical features –

- Bleeding Per Anum. — (1)
- diarrhoea — (2)
- Incomplete defecation — (3)
- Painfull defaecation — (4)
- Mucus + Blood — (5)
- constipation — (6)

## Spread of CA –

- Local spread — (1)
- lymphatic spread — (2)
- Blood spread. — (3)
- Peritoneal spread — (4)

## Stages of CA –

- Stage A – limited growth — (1)
- Stage B – extended growth — (2)
- Stage C – Lymp. Nodes Involve — (3).

- diagramatic Presentation —

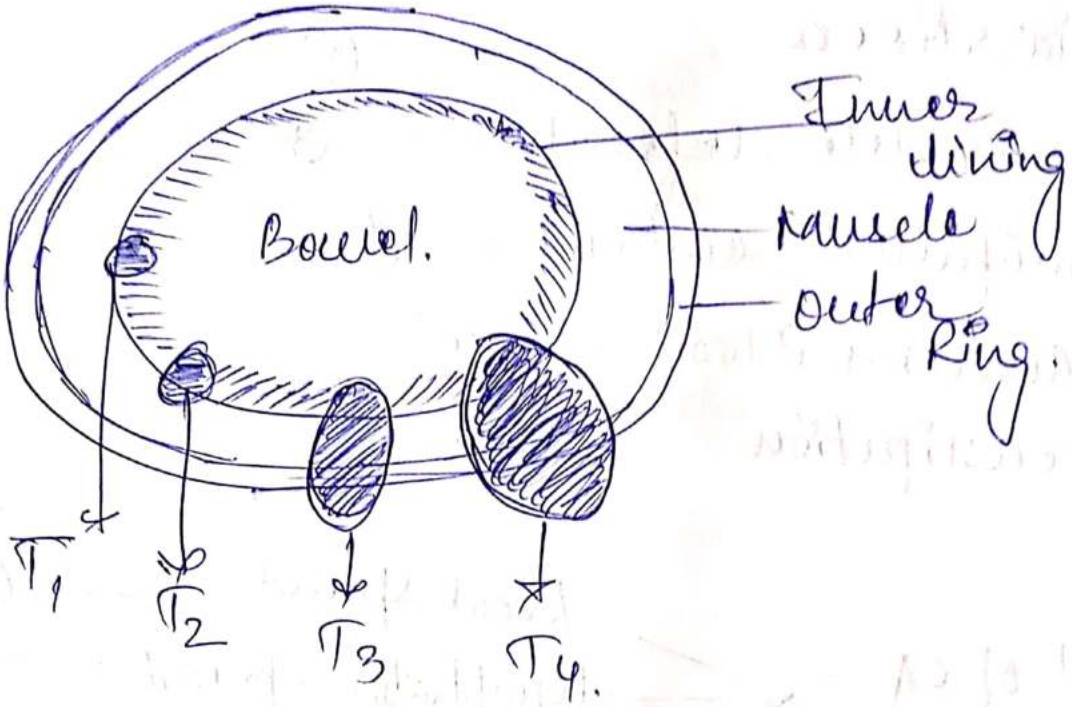


— TNM classification —

— Tumor — T0 — No tumor
— T1s — CA in situ
— T1 — Invasion submucosa
— T2 — Muscularis Propria
— T3 — Peri Rectal tissue
— T4 — Visceral peritoneum Involve

- Lymph Node —

N0 — No spread — (1)
N1 — 1-3 Nodal spread — (2)
N2 — 04 Nodal spread — (3)

- Metastasis —

- M0 — No spread — (1)
- M1 — Distant spread — (2).

Investigations —

- Proctoscopy — (1)
- Sigmoidoscopy — (2)
- Barium enema — (3)
- Colonoscopy — (4)
- TRUS (Transrectal) — (5)
- EUS. (Endorectal) — (6)
- USG — (7)
- CT Scan. — (8).

- Treatment -

— Radiotherapy — ① — Pre-operative
— Post-operative
— InterActive.

— chemotherapy.

— Surgery. — HAR — (High-Anterior Res
— APR — (Abdomino-PR)
(Perine
— LAR — (Low A-R.)

— Hartmann's operation

# Rectal Polyp :

Rectal Polyp – It's directly co-relates with the – Colorectal Polyp.

It's directly co-relates with the small clump of cells that forms on lining of colon.

Factors

- Benign — ①
- Malignant — ②
- unknown cause — ③
- Polyp formation — ④
- Hereditary — ⑤.

Clinical features –

- Rectal Bleeding — ①
- Abdominal cramp — ②
- Prolapsed — ③
- watery diarrhoea — ④.

- diagram —

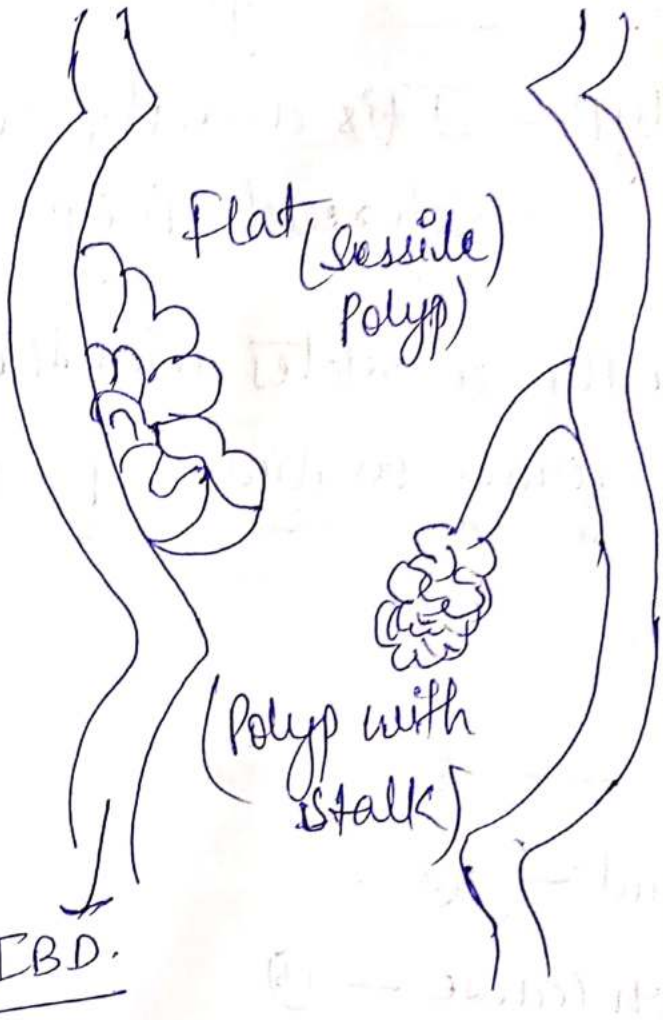


- Diagnosis -
  - Proctoscopy —— (1)
  - Sigmoidoscopy —— (2)
  - colonoscopy —— (3).

- Treatment — Polypectomy

# Juvenile Polyp

- Single in 70%, May be Multiple (3 or 4) — (1)
- Oval in shape — (2)
- Pendunculated and spherical — (3)
- Smooth — (4)
- Bright red colour — (5)

## Clinical features -

- No tendency — (1)
- Bleeding — (2)
- Defecation — (3)
- Anaemia — (4)
- Pain — (5)

**Treatment** - Excision — (1)
- Electrothermic — (2)

## Anal Incontinence (मलत्याग)

- Anal Incontinence is directly co-relates with inability to control Bowel Movements
- Voluntary control the Anal sphincter is called Anal Incontinence.

**Factors**

- Contraction — (1)
- Cerebrum — (2)
- lumbo sacral Region — (3)
- Rectum — (4)
- Anal canal (80°) — (5)

**Types** — (1) Partial — (1)
(2) complete — (2).

- **Partial** — loses only small Amount of liquid wash
- **Complete** — Entire solid Bowel Movement — (2).

Causes -

- Denervation — (1)
- Damage — (2)
- Descent — (3)
- Debility — (4)
- Destruction — (5)

Treatment -

- Temporary Incontinence — (1)
- Permanent Incontinence — (2)

(1) Temporary Incontinence -

- Reassurance — (1)
- Perineal exercise — (2)
- Kegel excercise — (3)

Permanent Incontinence -

- sphincteroplasty — (1)
- Replacement sphincter — (2)
- graciloplasty — (3)
- colostomy — (4).

(1)

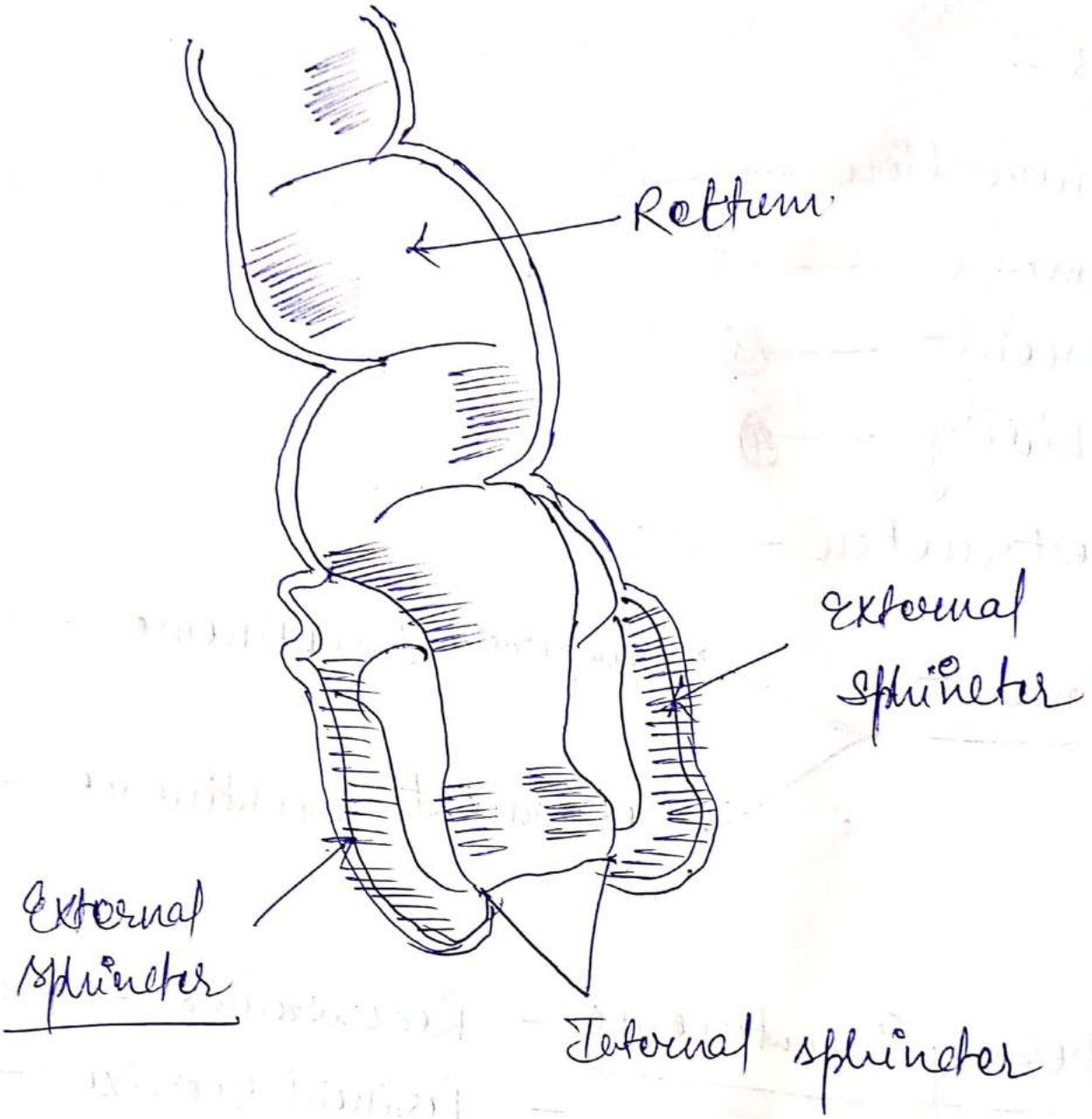


Sectored Anal sphincter muscles.

# • गुदभ्रंश • (Rectal Prolapse)

निदान – प्रवाहरण — (1)
– अतिसार — (2)
– रूक्ष आहार — (3)
– दुर्बल — (4)
– वेदना — (5)

लक्षण – ज्वर — (1)
– छर्दि — (2)
– गुद वेदना — (3)
– अतिसार — (4)
– अजीर्ण — (5)
– श्वास — (6)
– कास — (7)

चिकित्सा – स्वेदन — (1)
– स्नेहन — (2)
– prolapsed गुद — (3)
– मोकण बन्ध — (4)

} चिकित्सा

- शमन औषधि -

- मुषाका तैल - Take dead Rat
  - mix with बृहत पंचमूल

- चंगेरी घृत - used orally.

# • Rectal Prolapse •

Rectal Prolapse directly co-relates with the condition in which part of large Intestine slips outside the Anus.

M : F = 1 : 6.

factors -

- Infants — ①
- childrens — ②
- Adults — ③

① Infants - underdeveloped sacral curve — ①
- Diminised tone — ②
- Anal Musculature — ③

② childrens - Habitual constipation — ①
- whooping cough — ②
- Diarrhoea — ③.

- Adults – common in females — (i)
  - Prolonged labour — (ii)
  - excessive straining — (B)

- diagram –

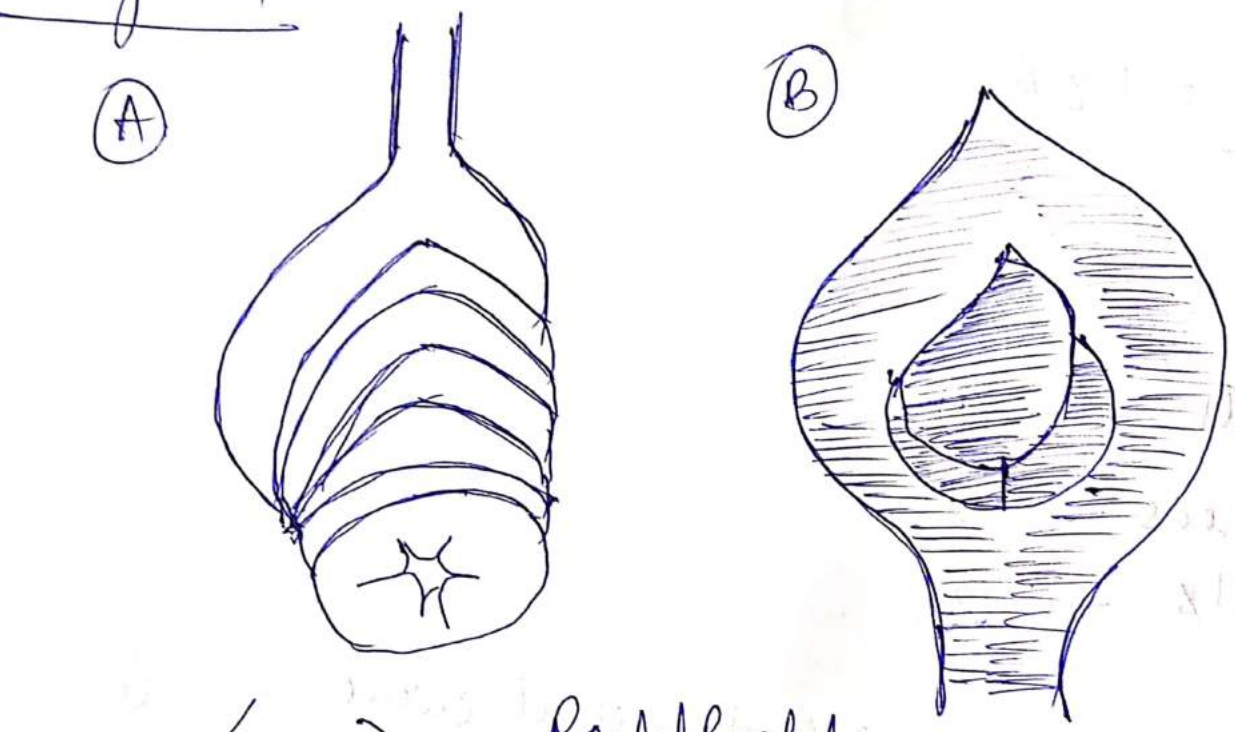


– Rectal Prolapse –

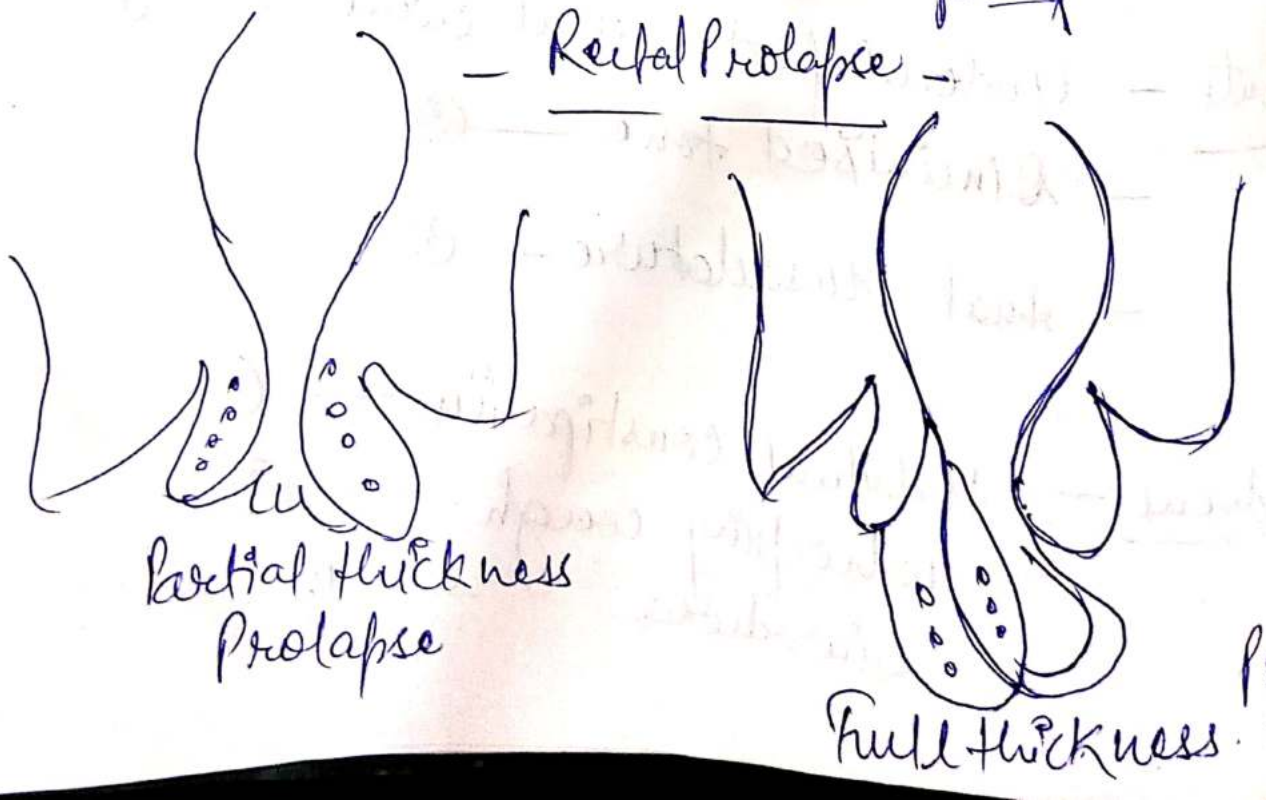

## Clinical features —

- Mass per Anum. — (1)
- squating position — (2)
- Pink in colour — (3)
- circumferential — (4)
- slight mucus discharge — (5)

## Treatment -

(1) conservative — Avoid straining — (1)
— control diarrhoea — (2)
— Digital Reposition — (3)
— Nutrition — (4)
— Sub mucosal. — (5)

(2) surgical — theirsichs operation — (1)
— Goodsalls operation — (2)

- Grades :- Degree

- 1° degree — (1)
- 2 degree — (2)
- 3 degree — (3)
- 4 degree — (4)

- Grade-01 - occult Prolapse — (1)
- Grade-02 - Prolapse — (2)
- Grade-03 - Protrusion Beyond Anus — (3)
- Grade 04 - ~~[illegible]~~ Rectal completely out — (4)

- cystocele - Most common type of Prolapse

- 03 types of ~~[illegible]~~ - Bladder Prolapse
  - cystocele
  - urethrocele
  - cystourethro

## Complete Prolapse (Procedentia)

- often associated with uterine prolapse — (1)
- entire wall of Rectum palpated — (2)

**Causes. -**

- Bowel Habit — (1)
- Laxity — (2)
- Lack of Rectal fixation — (3).

**Clinical features -**

- Mass per Annum — (1)
- Constipation — (2)
- Incontinence faeces — (3)
- Excessive Mucus discharge — (4)
- Rectal Examination — (5)
- Sepsis — (6).

- Investigation
  - Defecography. — (1)
  - Sigmoidoscopy — (2).

- Treatment
  - Peri Anal Procedures — (1)
  - Abdominal Procedures — (2)
  - Delorme's Procedures — (3)
  - Altmier's Procedure — (4)
  - Theirsch wiring — (5)
  - Well's operation — (6).
  - Mesh Recto pexy — (7).


- Delorme's Procedure

- आयुर्वेदिक चिकित्सा
  - मुष्क तैल पिन्डु — (1)
  - चंगेरी घृत — (2)
  - T-Bandage — (3)
  - अश्वगन्ध अवलेह — (4)
  - Perineum exercise — (5).

# • FISTULOGRAPHY •

Fistulography is directly co-relates with the Fistulogram.

It's Medical test that uses fluoroscopy

It's Important diagnostic tool

- Factors —

— Diagnosis of course — (1)
— Extension — (2)
— Branching — (3)
— External opening — (4)

Contrast Media — diatrizoate sodium

Material Required —

— Fistulogram tray — (1)
— urograffin 60% — (2)
— 2-4 ml of dye — (3)
— Good x-Ray Machine — (4)

— Inj dexamethasone

- Tray –

– Malecot catheter — (1)
– Disposable syringe — (2)
– condom – 1 Pair — (3)
– Rubber bag — (4)
– Gloves — (5)
– Plain thread — (6)
– xylocaine Jelly — (7).

# • Fistula IN Ano. •

Fistula in Ano is directly co-relates with the Inflammatory track Infection.

- Infected tunnel B/w skin and Anus.

**Factors** –

- Internal opening — (1)
- External opening — (2)

**Internal opening** – Primary — (1)

**External opening** – Secondary — (2)

**Causes.** –

- Anal gland Infection — (1)
- Abscess — (2)
- Infection — (3)
- TB — (4)
- Crohn's diseases — (5)
- ulcerative colitis — (6)
- CA Rectum — (7)
- Trauma — (8).

- classification –

– standard – subcutaneous — ①
– submucous — ②
– low level — ③
– high level — ④
– pelvirectal — ⑤

- Park's classification –

– Inter-sphincteric — ① 70%
– Trans-sphincteric — ② 25%
– supra levator — ③ 4%
– extra sphincteric — ④ 1%

diagram –

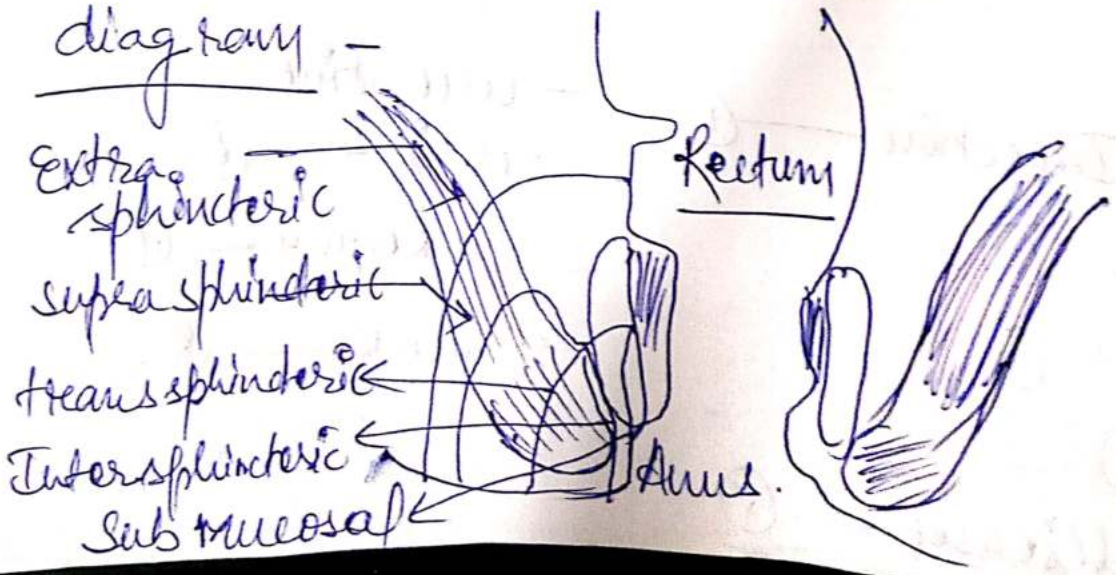

# • Goodsall's Rule •

Goodsall is directly co-relates with the External opening of Anal fistula to Internal opening.

factors –

- Perianal skin —— ①
- Transverse Anal line —— ②
- Midline —— ③
- Curve course —— ④.

diagramatic Presentation –

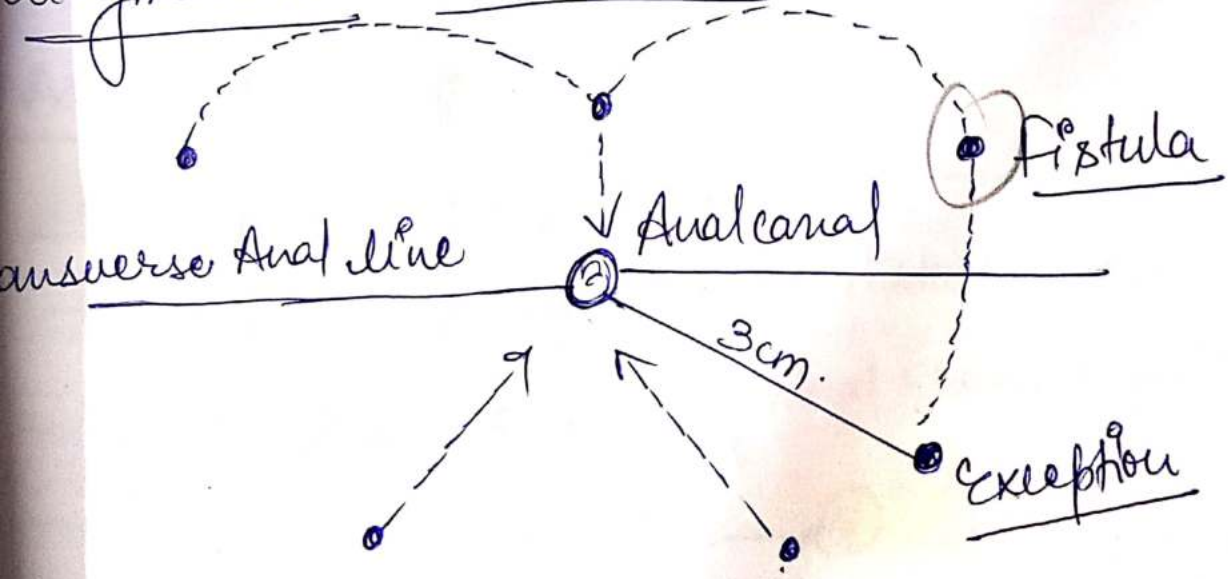


Anterior – Straight tracts –

- Clinical features —

— Gland Infection —— (1)
— Pruleent discharge —— (2)
— external opening —— (3)
— Horse shoe fistula —— (4)
— Pain Increases —— (5)

## Treatment –

- Fistulotomy —— (1)
- Fistulectomy —— (2)

## आयुर्वेदिक चिकित्सा –

- अपमार्ग क्षार सूत्र —— (1)
- त्रिफला गुग्गुलु —— (2)
- गन्धक रसायन —— (3)
- अनुलोमा D.S. —— (4)
- Sitz Bath —— (5)

## Advance techqiques –

- Anal fistula Plug (AFP) —— (1)
- Ligation Inter Sphincteric Fistula track (LIFT) —— (2)
- Video Assisted Anal fistual track ligation —— (3)
- Fistula clip closure —— (4).

- Diagram II —

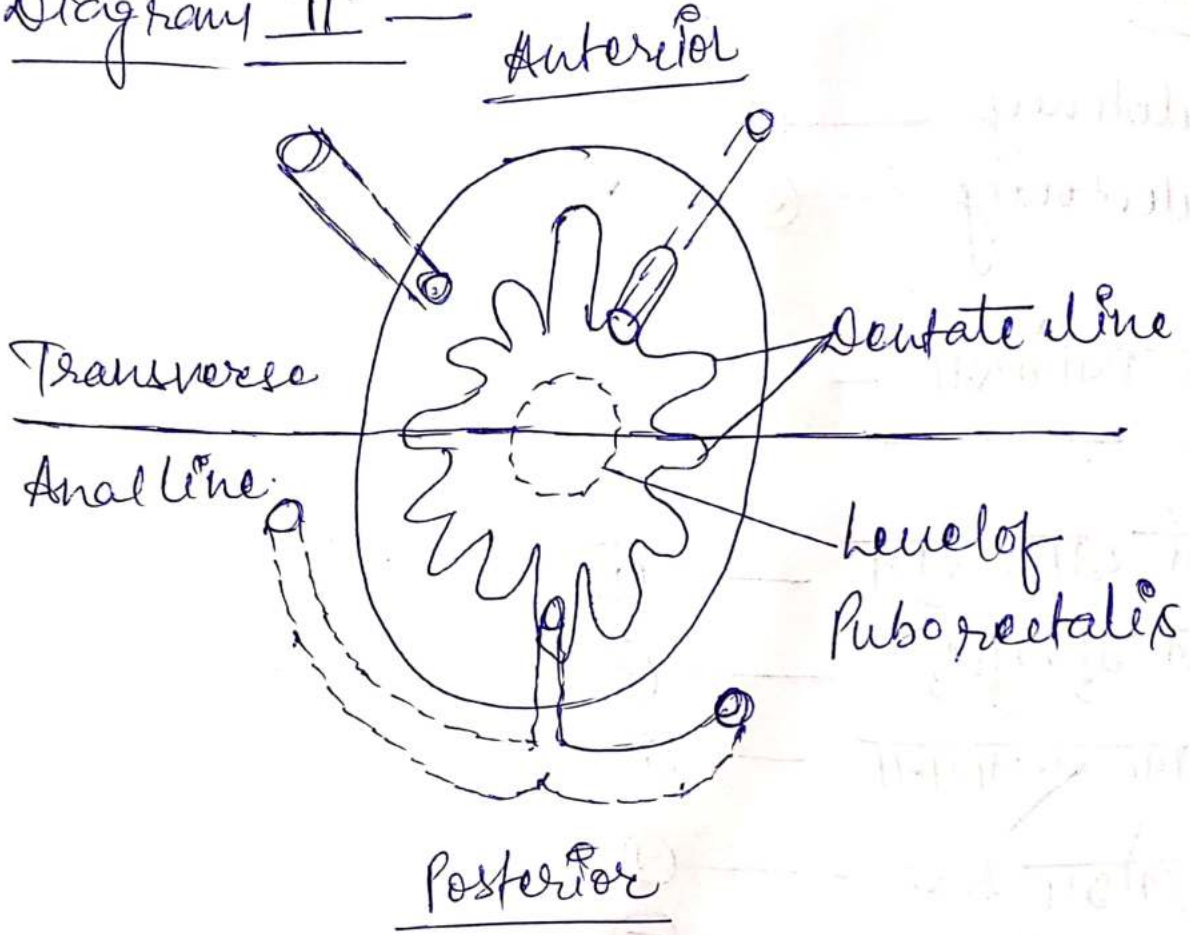


- Examination —

— Inspection —— (1)
— Digital examination —— (2)
— Proctoscopy —— (3)
— Probing —— (4).

# भगन्दर (Fistula In Ano)

Fistula in Ano is directly co-relates with the Inflammatory track Infection.

Infected tunnel B/w skin and Anus.

- निदान – Riding over आहार: — (1)
  - Riding over जल: — (2)
  - troublesome postures — (3)
  - अर्श निदान — (4)
  - साधु गर्हणे: — (5)
  - पूर्वजन्म पाप: — (6)
- संप्राप्ति –
- पूर्वरूप – कटी वेदन — (1)
  - कपाल वेदन — (2)
  - कण्डू — (3)
  - छाद — (4)
  - शोफ — (5)
  - गुद शोफ — (6)

• संप्राप्ति - मिथ्या सेवन — (1)

↓

Pidika formation — (2)

↓

अंगुल from Anus Internally —

↓

Leads to रक्त मांस विकृती —

↓

Resulting sinus formation — (5)

↓

pus discharge — (6)

↓

भगन्दर occurs. — (7)

• प्रकार - A/c to सुश्रुत - 05.

- वातज — (1)
- कफज — (2)
- अगन्तुज — (3)
- वात-कफज — (4)
- पित्तज — (5)
- सन्निपातज — (6)
- वात-पित्तज —
- पित्त-कफज —

(1) प्राचीन (Blind
(2) अर्वाचीन (Blind Intern

Another types. —

- ऊर्ध्वग्रीव भगन्दर —— (1)
- परिस्रावि भगन्दर —— (2)
- उन्मार्गि भगन्दर —— (3)
- ऋजु भगन्दर —— (4)
- भग्नी भगन्दर —— (5)

(1) ऊर्ध्वग्रीव भगन्दर — पित्तप्रकोप —— (1)
— Produce रक्त, तनु —— (2)
— दाह —— (3)
— दुर्गन्ध —— (4)

परिस्रावि भगन्दर:

पिडिका — शुक्ल
— कण्डूवत
स्राव — पिच्छिल
वेदना — कण्डू

(2) उन्मार्गि भगन्दर

दोष – वात पित्त origin — (1)
– circular type — (2)

– पिडिका – श्यावा ; ताम्र

– लक्षण – दाह — (1)
– ओश — (2)
– मोहरा रूप — (3)
– गुद वेदना — (4)

(4) ऋजु भगन्दर –

दोष – वात-कफ — (1)
पिडिका – पाण्डु — (2)
– श्याव — (3)
लक्षण – कृच्छ्र पाक — (1)
straight track. — (2)

(5) अर्शो भगन्दर – – दोष – कफ and पित्त — (1)
– पिडिका – अर्श — (1)
– straight track — (2)
– लक्षण – शोफ — (1)
– कण्डू — (2)
– दाह : — (3)

साध्य / असाध्यता — कृच्छ्र साध्य — एकदोषज, द्विदोषज
— असाध्य — त्रिदोषज, क्षतज

चिकित्सा — विरेचन — (1)
— वमन — (2)
— पाचन — (3)
— शोधन — (4)
— तैल दाह — (5)
— क्षारसूत्रेण — (6)
— व्रणवात चिकित्सा — (7).

अपथ्य — अति व्यायाम — (1)
— मैथुन — (2)
— क्रोध — (3)
— sexual intercourse — (4)
— गुरु आहार सेवन — (5)
— Animals Riding (on) — (6)

भगन्दर नाशक योग —

— भगन्दर नाशक तैल — (1)
— स्थानदन तैल — (2)
— गुडुचीमादी तैल — (3)
— त्रिफला योग — (4)
— अभयरिष्ट — (5)
— यष्टिमधु तैल — (6)
— विडंगादी तैल — (7)
— रुजठी योग — (8)

• diagram —

# Ano-Rectal Abscess (गुद-विद्रधि)

- Ano-Rectal Abscess is directly co-relates with the Abscess.
- Abscess around lower Rectum and Anal canal is known as Ano-Rectal Abscess.

Factors —

- Abscess — (1)
- Lower Rectum — (2)
- Anal canal — (3)
- Pyogenic Infection — (4)

Causative factors —

- E-coli — 60% — (1)
- Bacteroides — (2)
- Staphylococcus Aureus — (3) 23%.

- Causes -

- Anal gland Infection — ① 90%
- Blood Infection — ② 10%
- Irritation — ③ 100%
- Low Immunity — ④
- Ano rectal injury — ⑤

- Types -

- Peri-Anal — 60% — ①
- Ishio-Rectal — 30% — ②
- Submucus. — 5% — ③
- Pelvi-Rectal — 40% — ④

• Major types areas follows :-

- Peri-Anal — ①
- Ishio-Rectal — ②
- Submucus — ③
- Pelvi-Rectal — ④.

# • Peri-Anal Abscess •

- Peri-Anal Abscess directly co-relates with the Near to Anal canal.

- Causes — Suppuration — (1)
  - Infection — (2)
  - Hematoma — (3)

- Clinical features —
  - Severe pain — (1)
  - Fever — (2)
  - Headache — (3)
  - Pruritis — (4)
  - Acute Angry lump — (5)

- Treatment —
  - Sitz Bath — (1)
  - Analgesics — (2)
  - Antibiotic cover — (3).

# Ischio - Rectal Abscess

- Causes - Extension of Anal Inflammation —
  - Infection (Blood) — ②

- Factors - Superior — ①
  - Inferior — ②
  - Medial — ③
  - Lateral — ④

- Clinical features -
  - Severe throbbing Pain — ①
  - High grade fever — ②.

- Examination -
  - Tender — ①
  - Swelling — ②
  - Fluctuation — ③
  - Pain — ④
  - Lesion Bogginess — ⑤

Bottom Abscesses.

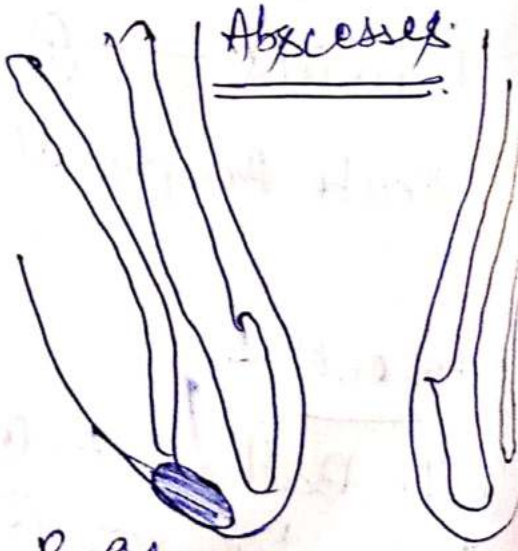

Peri Anal Abscess.

Ischio Ab

- Treatment — under Antibotic cover — ①
- Incision — Cruciate — ②

Ⓐ

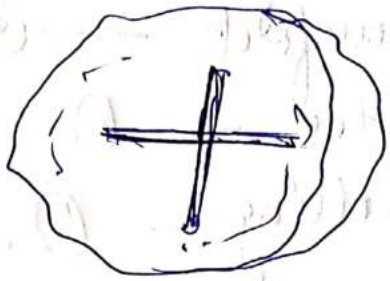

Ⓑ



Cruciate Incision

- Sub — Mucus. Abscess.

- directly correlates with the Deep Mucus Memb.

- cause :-
  - Spread — ①
  - Mucous flow. — ②
  - Mucous Infection — ③
  - Haemorrhoid — ④.

Clinical features —

- Pain in Ano-rectum — (1)
- Discomfort — (2)
- Tender — (3)
- Swelling — (4).

- Treatment —

- Sims forceps — (1)
- Proctoscopy — (2)
- Antibiotic control — (3).

- Pelvi-Rectal Abscess.

- In b/w the the Pelvic Region and Rectum.
- Pelvic- Peritoneum.

Causes. — Appendicitis — (1)
— Crohn's disease — (2)
— salpingitis — (3)
— sepsis — (4).

Clinical features -

- Deep tenderness. —— ①
- Deep pain —— ②
- painful faecal discharge —— ③
- Swelling —— ④
- Pus discharge —— ⑤
- Rectum swellings —— ⑥

Treatment -

- Cover under Antibiotics —— ①
- Nick Made —— ②
- Drain Pus with sinus forceps —— ③.

# Anal fissure (परिदरिका)

- Anal fissure is directly co-relates with the small tear in the Anus Boundaries.
- Also called — Anal ulcer
- occurs when passing hard and Hard stools.

## Factors -

- Locations — (1)
- Types. — (2)
- Clinal features — (3)
- Examinations — (4)
- Treatment — (5)
- आयुर्वेद चिकित्सा — (6)

(1) Locations -
- Anterior } Male → 10%
- Posterior } Male → 90%
- Anterior } Female → 40%
- Posterior } Female → 60%

- Types - Acute — (1)
  - Chronic — (2).

(1) Acute - Initial Pain — (1)
- constipation — (2)
- Deep tear — (3)
- Inflammation — (4)
- Spasm — (5)

(2) — Chronic — Severe Pain — (1)
- More than 6 weeks — (2)
- Severe Inflammation — (3)
- Canoe shaped Ulcer — (4)
- Sentinel Pile — (5)
- Hypertrophied Anal Papillae — (6).

- Clinical features - Pain — (1)
- Bleeding — (2)
- Constipation — (3)
- Discharge — (4).

## On examination -

- Inspection — (1)
- Digital examination — (2)
- Rectoscopy — (3)
- Proctoscopy — (4).

## Treatment -

- General — (1)
- Conservative — (2)
- Surgery — (3).

**General**

- Avoid constipation
- soft stool.
- fluid intake
- Diet rich fibre
- Sitz bath

**Conservative** -

- Oral Medicine — (1)
- Stool softener laxative — (2)
- ointments — (3)
- Inj Bottulinum — (4).

**Surgery** -

- Anal Dilatation — (1)
- Fissurectomy — (2)
- sphincterotomy — (3)
- Anal Advancement flap — (4).

- आयुर्वेदिक चिकित्सा

- तैल पूर्ण — (1)
- अग्नितुण्डी — (2)
- अग्निलेक्स (Ablilax) — (3)
- त्रिकल गुग्गुलु — (4)
- गन्धक रसायन — (5)
- cap. Grab. — (6)
- जातयादी तैल — (7)
- Sitz Bath: — (8).

# परिकर्तिका

- परिकर्तिका – All around
- कर्तिका – Act of cutting

- निदान – अति मृदु कोष्ठ — (1)
  - अतिलवणं — (2)
  - पीत औषध — (3)
  - मन्द अग्नि — (4)
  - रूक्ष आहार — (5)
  - प्रदूष्य — (6)
  - विरेचन व्यापत — (7)
  - बस्ति व्यापत — (8)

- लक्षण – दाहः — (1)
  - स्राव — (2)
  - नाभि भेदा — (3)
  - परिकर्तन — (4)
  - वायु विष्टम्भा — (5)
  - रुचि — (6)

• संप्राप्ति –

निदान सेवन – (1)

↓

पीत औषध (2)

↓

Eat रूक्ष आहार (3)

↓

Sharp Medicines. (4)

↓

रक्त vitiated (5)

↓

दोष Aggravated (6)

↓

लघु आंत्र formation (7)

↓

Bowel hargeness. (8)

↓

Anal fissure occurs. (9).

– चिकित्सा – दीपन–पाचन (1)

– वात–पित्त शमन (2)

– वात नुलोमन (3)

– शीतल लेप (4)

– cap – Grab (5)

– अभयारिष्ट

– अग्नितुण्डि वटि

– जात्यादी घृत

– Ointments

# ◦ अर्श ◦

- अर्श directly co-relates with the Haemorrhoids

- निदान - अत्याशन - Excessive eating) — ①
  - अध्याशन
  - विरुद्ध आशन - (Antagonist food) — ②
  - स्त्रीप्रसंग (Excessive coitus) — ③
  - वेगविधारण (Suppression of urges) — ④
  - मन्दाग्नि

- संप्राप्ति -

निदान सेवन — ①

↓

दोष vitiation — ②

↓

रक्त दोष added — ③

↓

move downwards — ④

↓

महास्रोतनी — ⑤

↓

reaching guda → अर्श occurs. — ⑥

- पूर्वरूप — अन्न अश्रद्धा — (1)
  - परिदाह — (2)
  - विषस्तम्भ — (3)
  - पिपासा — (4)
  - अतोष — (5)
  - कार्श्य
  - उदगार बहुत्व — (6)
  - अन्त्र कूजना — (7)
  - पाण्डु रोग — (8)
  - श्वास — (9)
  - कास — (10)
  - शोथ — (11)
  - तन्द्रा — (12)
  - निद्रा — (13)

- types — According to origin — (1)
  - According to character — (2)
  - According to दोष — (3)
  - According to site — (4).

(A) According to origin -

- सहज — (1)
- जन्मोत्तर — (2)

(B) A/c to charaction -

- शुक्र — (1)
- अर्दर — (2)

(C) A/c to दोष :-

- वातज — (1)
- पित्तज — (2)
- कफज — (3)
- द्वंद्वज — (4)
- सन्निपातज — (5)
- रक्तज — (6)

A/c to site -

- बाह्य - (सम्भवारिणी) — (1)
- आभ्यन्तर - (प्रवाहीणी) — (2)

- रूप - वातज अर्शस - रूक्ष — (1)
- Reddish — (2)
- कण्डूयुक्त / तुण्डिकेरी — (3)
- दाह — (4)
- Painful Diarrhoea — (5)
- Blackish discoloureation —
- मूर्छा — (7)
- चोट suffers — (8)
- ज्वर suffers — (9).

(2) पित्तज अर्शस -
- Bluish colour — (1)
- यकृत प्रकोप — (2)
- Stool ~~st~~ Blood — (3)
- दाह — (4)
- urine yellowish — (5)
- ज्वर — (6)
- दाह — (7)
- पिपास — (8)
- मूर्छा — (9).

## - कफज अर्श -

- Resembles like गोस्तन — (1)
- भ्रमः — (2)
- दाहः — (3)
- Loose stools. — (4)
- शोफ — (5)
- शीत ज्वर — (6)
- अरोचक — (7)
- अविपाक — (8)
- शिरो गौरव — (9)

## रक्तज अर्श -

- गुंजा फल like — (1)
- Hard stools — (2)
- Painful — (3)
- दाहः — (4)
- शोफ — (5)
- Painful stools — (6)
- रक्त stools — (7).

• सन्निपातज अर्शस -

- Mixed features — (1)
- All त्रिदोषज features — (2)

• सहज अर्शस -

- दुषित शुक्र शोणित जन्य — (1)
- दुराचरण — (2)
- धारण — (3)
- पारुष — (4)
- अन्तरमुख अर्शस — (5)
- अतोप — (6)
- क्षेमस्वर : — (7).

• Complications -
- उपद्रव — (1)
- obstructions — (2)
- urine obstructions — (3)
- Chest Pain — (4)
- faeces pain — (5).

• चिकित्सा – भैषज साध्य — (1)
— क्षार साध्य — (2)
— अग्नि साध्य — (3)
— शस्त्र साध्य — (4)

• स्थानीय चिकित्सा –

— स्वेदन — (1)
— अवगाह — (2)
— अभ्यंग — (3)
— धूपन — (4)
— प्रलेप — (5).

Medical Management –

— गुडहरितकी — (1)
— तीतकी — (2)
— गुल्लालक — (3)
— पंचामूल गुड — (4)
— कल्याणक गुड — (5)
— पिप्पलयादी योग — (6)
— अभयरिष्ट — (7)
— चंगेरी घृत — (8).

- क्षार कर्म सम्यक लक्षणं

- वातज - पक्वा जम्बु colour — (1)
- पित्तज - मयूरकान colour — (2)
- कफज - वृहती पुष्प colour — (3)

- क्षारमान -

1.) पित्तज — नखः प्रमाण — (1)
- कफज — 02 times of Above — (2)
- वातज — 03 times of Above — (3).

- क्षार - प्रतिक्षारणीय क्षार — (1)

↓
Coagulations — (2)
↓
Disintegration — (3)
↓
Cauterization — (4)
↓
Necrosis — (5)
↓
Scar formation — (6)

↓
obliteration — (7)
↓
complete wound Healing — (8)

# • Haemorrhoids •

- Swollen and Inflamed Veins in Rectum and Anus.
- causes discomfort and Bleeding.

• Factors -

- Classifications — ①
- Causes — ②
- pathology — ③
- clinical features — ④
- Examination — ⑤
- Managements — ⑥

classifications -

- Internal Piles — ①
- External Piles — ②
- Internal - External Piles — ③
- Primary — ④
- Secondary — ⑤

① Internal Piles. – covered by Mucus Memb.

② External Piles – covered by skin

③ Internal-external – covered by Mucus and skin.

- Primary – Located – 3 o'clock — ①
  - 7 o'clock — ②
  - 11 o'clock — ③

② Secondary – Primary site

- causes. – Primary causes.
  - Hereditary — ①
  - Anatomical — ②
  - exciting cause — ③
  - Physiological cause — ④
  - Diet — ⑤

## Secondary Cause -

- CA (compressed superior Rectal Veins) — (1)
- Difficult Micturition — (2)
- Pregnancy — (3)
- Portal Hypertension — (4)

## Pathology.

- Pedicle — (1)
- Body — (2)
- external Haemorrhoids — (3)

## Clinical features -

- Bleeding Phase — (1)
- Prolapse Phase — (2)
- Pain — (3)
- Mucus discharge — (4)
- Anaemia — (5)

- Examination -

- Inspection —— ①
- Digital examination —— ②
- Proctoscopy —— ③

① Inspection -

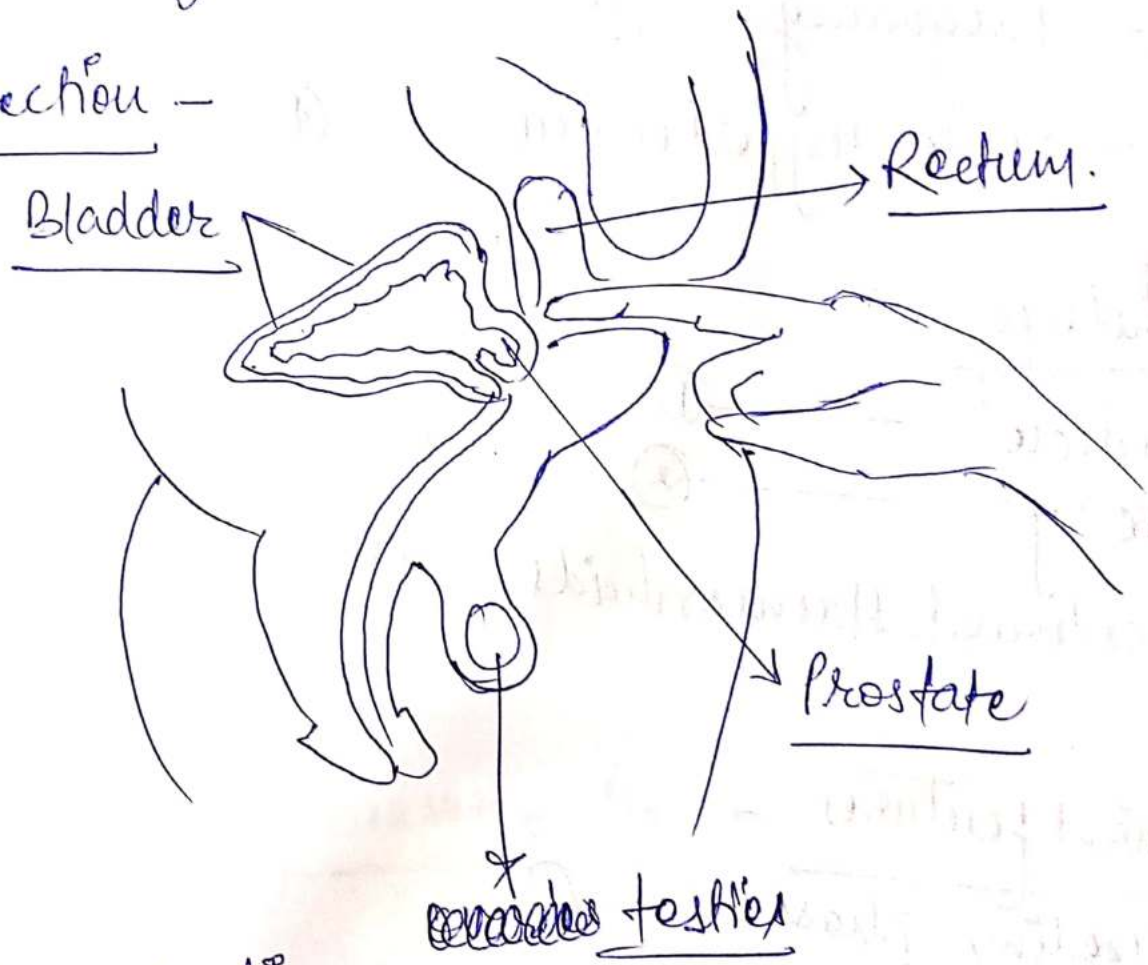


② Digital examination - complicated Piles. can be identified

③ Proctoscopy - through Proctoscopy examination

## Complications —

1. Profuse Bleeding — (1)
2. Strangulation — (2)
3. Thrombosis — (3)
4. Gangrene — (4)
5. Fibrosis — (5).

# • Fixation Modalities •

- Sclerotherapy — ①
- Barron Rubber band Ligation — ②
- Cryosurgery — ③
- Infra-Red coagulation — ④
- Haemorrhoidectomy — ⑤

## ① Sclerotherapy -

• Syringe — Gabriel / Disposable — ①

• contra-Indications — Prolapse — ②

- Inserted Proctoscope — ①
- drug is then Injected — ②
- Now, Injection should produce — ③
- causes fibrosis — ④
- Injected separately — ⑤

## Barron's Rubber Band Ligation :-

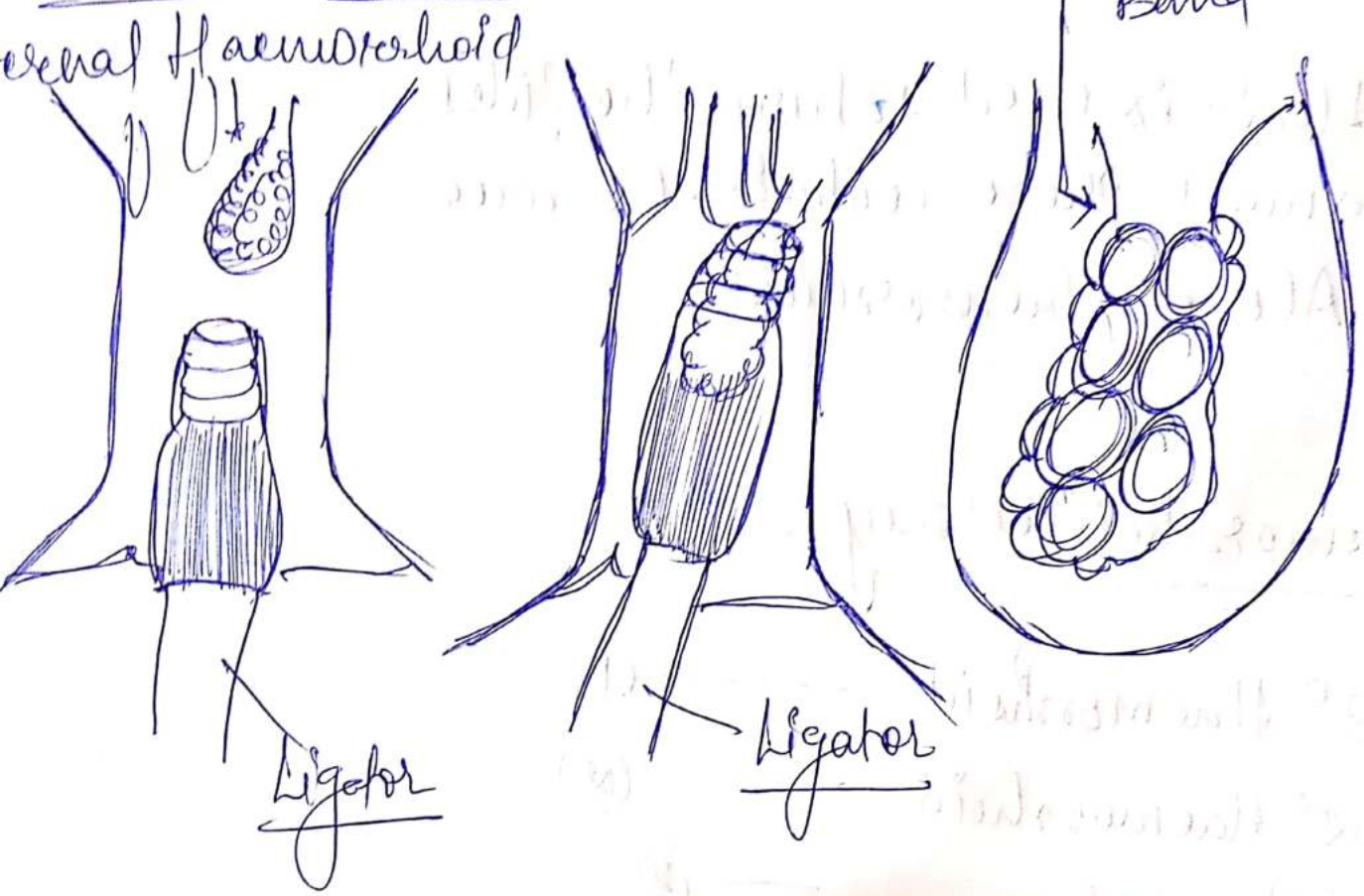


Cryosurgery - cellular destruction through freezing

- Both internal piles — ①
- external piles — ②
- Treated through one operation — ③

Liquid Nitrogen (−196°) Necessary

- Infra-Red coagulation -

- Heat is used to burn the piles
- Small probe contacts the area
- Above Haemorrhoid.

- Haemorrhoidectomy -

- 3° Haemorrhoid — (1)
- 2° Haemorrhoid — (2)
- Fibrosed — (3)
- Intero-external Haemorrhoid — (4)

- Contra-Indications - 1° Haemorrhoid — (1)
- Anaesthesia — Local / spinal — (2)
- Position — Lithotomy. — (3)
- general Anaesthesia is to be used.
- operation to Remove severe Haemorrhoids.

# सन्निरुद्धमल

— Comes under क्षुद्र रोग

— वेग सन्धारण — ①
— गुदमाश्रितः — ②
— महस्त्रोत : — ③
— सूक्ष्म द्वार — ④
— सौक्ष्म्यात — ⑤
— पुरीष — ⑥

संप्राप्ति —

— वेगअवरोध — ①
↓
वात विकृती — ②
↓
गुद आश्रय — ③
↓
महास्त्रोतस — ④
↓
Ano-Rectal lumen — ⑤
↓
Defecation — ⑥
↓
सन्निरुद्धमल occurs. — ⑦

चिकित्सा – Perform dilation — (1)
– नाड़ी यंत्र — (2)
– स्निग्ध अन्न — (3)
– परिशीक by वातहर वास — (4).

# Abdominal Injuries and their Management

- Abdominal Injuries is directly correlates with the severe subcutaneous Haemorrhages.

- Factors -

- Abdominal Laceration — (1)
- Intra Abdominal Haemorrhage — (2)
- Liver Rupture — (3)
- diaphragm Rupture — (4)
- Punctures — (5)
- Wounds — (6)

- Causes -

- collisions vehicle — (1)
- sport Injuries — (2)
- falls from Height — (3)
- Stab Injuries — (4)
- Assault — (5).

- Types:
  - Blunt — (1)
  - Penetrating — (2)

(1) — Blunt — Direct Impact
- (Haematoma)
- Liver
- spleen
- Kidney
- Intestine
- diaphragm
- Urinary Bladder

} Viscera Included

(2) Penetrating — Stabbing — (1)
- common liver site — (2)

o Clinical features -
- Abdominal Pain — (1)
- seat belt sign — (2) (seen in vehicle collision)
- Nausea, — (3)
- Vomiting — (4)
- Blood in Urine — (5)
- Fever — (6)

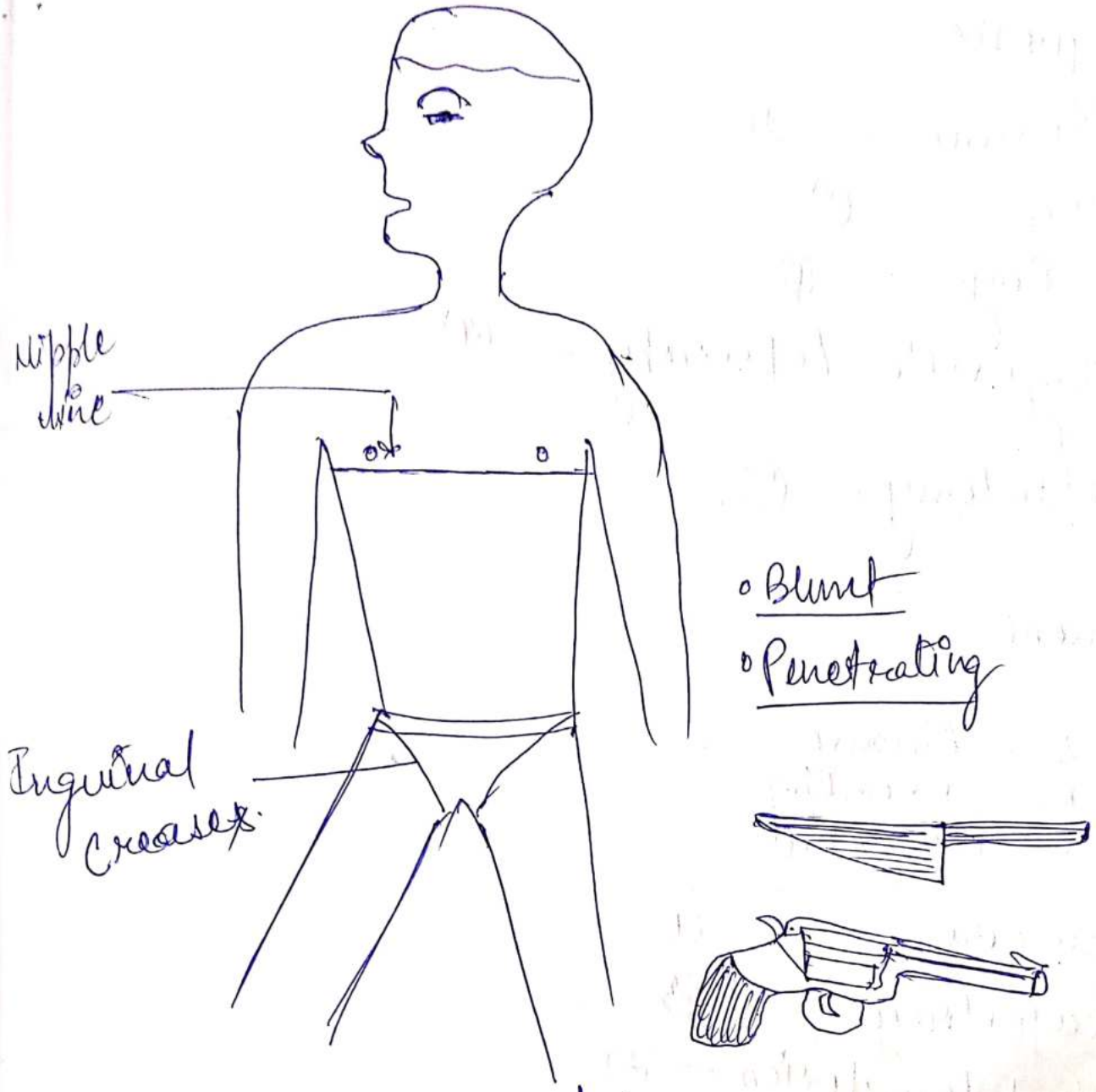


- Blunt
- Penetrating

- Abdominal trauma –

- Evisceration – Protrusion of Internal organs. — (1)
- London Sign's – Abrasion of Abdominal skin. — (2).
- Bone fracture — (3)
- shock — (4)
- organ Injury — (5).

- **Diagnosis** -

— CT scan — (1)

— USG — (2)

— X-Rays — (3)

— Diagnostic Laparoscopy — (4)

— Laprotomy — (5).

- **Treatment** -

— A — Airway
B — Breathing
C — Circulation.

— Surgery — (1)

— Laprotomy — (2)

— Blood transfusion — (3)

— Shock Management — (4)

— IV fluids — (5)